



Tartrazine-induced testicular toxicity: A mini review

S M Pathan, V T Dhurvey, A M Nagwanshi*, A A Sharma

Department of Zoology, RTM Nagpur University, Nagpur, Maharashtra, India

Abstract

Food additives are substances that are nowadays widely used to protect food, increase shelf life, and improve quality from the time of production up to the stage of consumption. Synthetic food dyes are one such category of food additives whose use has been increasing rapidly. Among them, tartrazine (E102) is a widely used synthetic food dye employed to impart color to food products. Increasing evidence suggests that tartrazine may exert adverse effects on male reproductive function, potentially leading to male sterility. This review summarizes experimental studies evaluating the effects of sub-chronic tartrazine exposure on male reproductive function. Reported findings include reductions in body and reproductive organ weights, hormonal disturbances characterized by decreased testosterone levels and altered luteinizing hormone (LH) and follicle-stimulating hormone (FSH) levels, and significant biochemical alterations. Biochemical parameters consistently demonstrate enhanced oxidative stress, reflected by increased lipid peroxidation and nitric oxide levels, along with decreased activities of antioxidant enzymes such as superoxide dismutase, catalase, and glutathione. Histopathological changes, including degeneration of seminiferous tubules, germ cell loss, Leydig cell damage, and impaired spermatogenesis, are commonly observed. Collectively, the evidence indicates dose-dependent male reproductive toxicity of tartrazine, largely mediated through oxidative stress and endocrine disruption.

Keywords: Tartrazine, synthetic food dye, male reproductive toxicity, oxidative stress, endocrine disruption, testicular histopathology, hormonal imbalance

Introduction

Food additives are substances added to food to preserve flavour or enhance its taste and appearance. Some additives have been used for preserving food by pickling, salting, preserving sweets. More than three thousand additives and preservatives are available in the market used as antioxidants and anti-microbial agents (Alaa *et al.*, 2016) [3]. Synthetic colours are man-made chemicals that do not exist naturally. Food colours are found to have an effect in the food choice by influencing taste, sweetness and pleasantness. Making the food products, many attractive types of natural and synthetic dyes were used. Natural food colorants are obtained from fruits, vegetables, and minerals and are generally considered safer than synthetic colorants. Among the natural food colorants approved by the FDA are annatto extract, beet juice, beta carotene, black/purple carrot, blue fruit juice color, blue shade vegetable juice colors, blue spirulina extract, butterfly pea powder, calcium carbonate, caramel color, elderberry, fruit juice, grape juice, hibiscus fruit, paprika, and purple carmine. Most natural colorant extracts are derived from plant tissues, and many are insoluble in water. There are three main types of natural dyes plant-based natural dyes obtained from plant sources, such as leaves, roots, bark, berries, and wood. Indigo, Logwood, and Henna are some of the most popular natural dyes. animal-based dyes, are derived from animal sources such as insects and invertebrates.

Comparatively, the synthetic food dyes are stable, less expensive and occupy an important place in food industry. Food Synthetic dyes are chemical compounds derived from coal tar or petroleum-based chemicals in a well-designed laboratory. Synthetic dyes are used for food coloring due to their several advantages and chemical properties, which enhance the overall look and feel of food items. They are

also widely used in various industrial applications, including drugs, cosmetics, textiles, plastics, and more, to enhance the visual appearance of products. Synthetic dyes are widely used due to their colouring properties, uniformity, stability and low cost. However, many of them become toxic after prolonged use, causing health problems such as indigestion, anaemia and allergic reactions as asthma and urticaria, pathological lesions in the brain, kidney, spleen and liver etc. (Visternicu *et al.*, 2025; Alla *et al.*, 2016) [3, 33].

The most common artificial food colours were azo dyes that included the aromatic azo compounds, such as tartrazine which is widely used (Visweswaran and Krishnamoorthy 2012) [34]. The annual global production of food azo dyes is estimated to be around 1 million tons, and more than 2000 structurally different dyes are currently in use (Elbanna *et al.*, 2017) [10]. About 65% of are used as food additives, in products such as soft drinks, jam, candy, pickles, etc. (Rovina *et al.*, 2017b; Sun *et al.*, 2023) [29, 31]. The most commonly used food azo dyes are Tartrazine (E102), Sunset Yellow (E110), Carmoisine (E122), Amaranth (E123), Ponceau 4R (E124), Allura Red AC (E129), Brilliant Blue (E 133), and HT Brown (E155) (Kaya *et al.*, 2021; Lipskikh *et al.*, 2018) [20, 22].

Tartrazine (E number E102) a synthetic azo dye with lemon yellow color, is a commonly used food colorant for food products that we eat almost every day (Khayyat *et al.*, 2017) [21]. Tartrazine is principally the trisodium 5-hydroxy-1-(4-sulfonatophenyl)-4-(4-sulfonatophenylazo)-H-pyrazol-3-carboxylate (Wopara *et al.*, 2021) [36]. Tartrazine used mainly to color several foods such as soft drinks, juices, biscuits, ice creams, sauces, mustard, snacks and decoration. It is also found in some medicines and beauty products like shampoos, perfumes, toothpaste, and soaps. In many developing countries, it is often used in cooking instead of saffron. The safe amount for people to eat is 0 to 7.5

milligrams for every kilogram of body weight (Mehedi 2009) [26]. Tartrazine has been shown to cause toxic effects on several body organs, including the liver, kidneys, and reproductive system. Studies suggest that high or prolonged exposure to Tartrazine may lead to organ damage, hormonal imbalances, and reduced fertility (Amin *et al.*,2010; Gao *et*

al.,2011) [5, 14], In the reproductive system, it may affect sperm quality, hormone levels, and overall reproductive health. These effects are more likely when the dye is consumed in large amounts or over a long period (Elekima and Nwachuku 2019) [12].

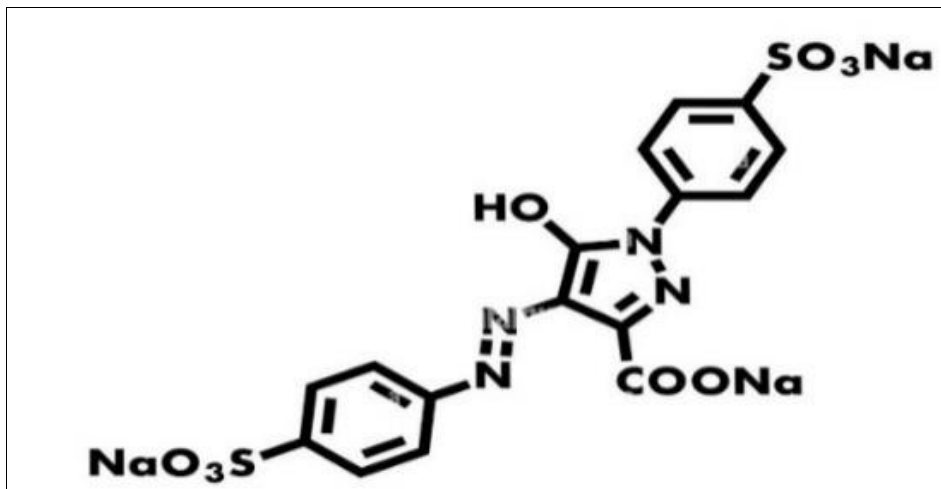


Fig 1: Structure of tartrazine (Source: <https://www.alamy.com/tartrazine-e102-food-dye-molecule-yellow-azo-dye-used-in-food-beverages-pharmaceuticals-etc-allergenic-skeletal-formula-image457067081.html>)

Mechanism of toxicity of Tartrazine

Tartrazine changes the cellular functions, tissue integrity, and the behavior of an organism by producing ROS that induces the inflammatory response via the overproduction of proinflammatory cytokines interleukin, 1 (IL,1) and interleukin, 6 (IL,6) altering enzymatic activity, and becoming a neurobehavioral disorders source that impairs the learning and memory processes as well. Biologically, from a mechanistic standpoint, OS has been recognized

as the main pathway that mediates the toxic effect of TZ, thereby leading to the imbalance of pro, oxidants and antioxidants in cells. This imbalance is evidenced by the increased levels of malondialdehyde (MDA), a marker of lipid peroxidation, which reflects the elevated oxidative damage. At the same time, the levels of endogenous antioxidant enzymes such as superoxide dismutase (SOD) and catalase (CAT) are frequently highly decreased, thus confirming the pro, oxidant shift caused by TZ exposure (Visternicu *et al.*,2025) [33].

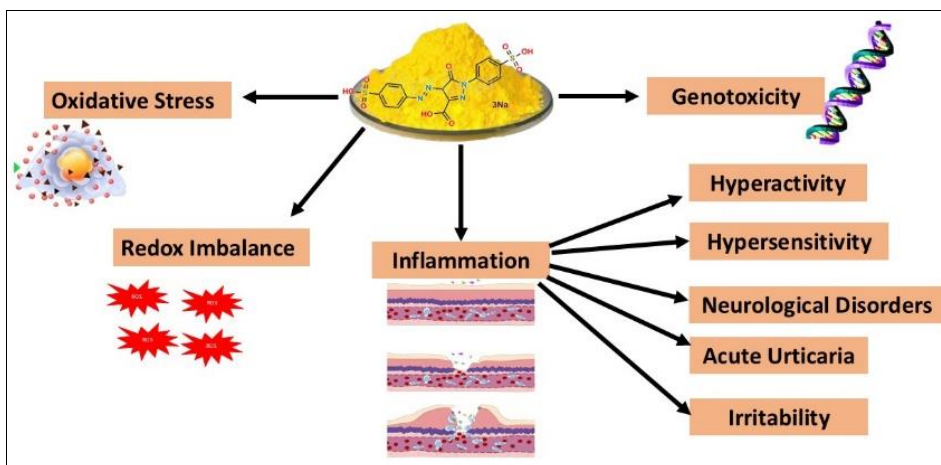


Fig 2: Mechanism of toxicity of Tartrazine (Visternicu *et al.*,2025) [33]

Methodology

The author followed PRISMA, the Preferred Reporting Items for systematic Reviews and Meta-Analyses. Recommendations are a minimal collection of things based on evidences. The author focused on both experimental and non-experimental studies, using internet databases, including Google Scholar, Pub-Med, Science Direct, and Research articles published between and were searched for

using search engines. Research article published between 2009 to 2025 were searched for using search engine.

Effects of Tartrazine of histological structure of testes

The testes are highly sensitive organs with a complex histological structure, primarily composed of seminiferous tubules where sperm production (spermatogenesis) occurs, and interstitial tissue containing hormone-producing Leydig

cells. Various toxicants can disrupt these structures, leading to impaired fertility (Martinot *et al.*,2018) [23]. Histopathologic examination of the testis is the most sensitive means to detect effects on spermatogenesis; however, the complexity of testicular histology, interrelatedness of cell types within the testis, and long duration of spermatogenesis can make assessment of a testicular toxicant challenging (Vidal and Whitney, 2014) [32]. Tartrazine exerts pronounced toxic effects on testicular structure and function, particularly targeting the seminiferous tubules and the spermatogenic process. Some studies have reported degeneration and disorganization of seminiferous tubules, accompanied by loss of normal spermatogenic architecture and reduced testicular weight, indicating compromised spermatogenic efficiency and direct gonadal toxicity (Mehedi *et al.*,2009; Gautam *et al.*,2010) [26, 15]. These findings provided the clear indications that tartrazine interferes with testicular integrity. Histopathological studies revealed vacuolation and degeneration of the germinal epithelium, disruption of spermatogenic layers, and impaired progression of germ cells from spermatogonia to mature spermatozoa (Visweswaran & Krishnamoorthy, 2012; Hoseinpouran *et al.*,2015) [34, 18]. Structural damage was often accompanied by tubular shrinkage, dilation, and distortion of interstitial tissue, suggesting that tartrazine toxicity is not confined to germ cells but also affects the supportive and endocrine components of the testes, including Leydig cells (Elekima & Nwachuku, 2019; Meghapriya & Kishori, 2019) [12, 25]. Studies have demonstrated the involvement of oxidative stress in causing the testicular toxicity evidenced by

increased lipid peroxidation, DNA damage, inflammatory responses, vascular congestion, and interstitial edema. These alterations culminate in arrested or severely impaired spermatogenesis, reduced sperm density, and, in severe cases, azoospermia (Boussada *et al.*,2017; El-Rabey *et al.*,2019; Hanna *et al.*,2023) [8, 11, 16]. Chronic and high-dose exposures further intensify these effects, leading to fibrosis, collagen deposition, necrosis, and marked atrophy of seminiferous tubules, confirming dose- and time-dependent histological injury (Ara *et al.*,2022; Shok *et al.*,2024; Ibrahim *et al.*,2024) [6, 30, 19].

Recent studies have expanded these observations by demonstrating reductions in germinal epithelium height, seminiferous tubule volume, and Leydig cell populations, along with decreased proliferative activity within the testes (Nazari *et al.*,2024) [28]. Specialized experimental models, including diabetic animals and developmental exposure paradigms, revealed aggravated damage characterized by severe architectural disorganization, hemorrhagic areas, interstitial hypoplasia, and long-term impairment of testicular development in offspring (Bassit & Ismael, 2025) [7]. These findings highlight the heightened vulnerability of compromised physiological states and developing testes to tartrazine toxicity. Importantly, several investigations demonstrated that co-administration of antioxidants or protective agents significantly restored near-normal testicular histoarchitecture, reduced oxidative damage, and improved spermatogenic activity, underscoring oxidative stress as a central mediator of tartrazine-induced reproductive toxicity (Al-Seeni *et al.*,2018; Abdella *et al.*,2025; Hegazy *et al.*,2023) [4, 2, 17].

Table 1: Histological changes in testes induced by tartrazine

Model organisms	Dosage	Duration	Histological changes	Reference
Adult male (<i>Rattus norvegicus</i>)	0.1%,1% and 2.5%	13 weeks	Degeneration and disorganization of seminiferous tubules with loss of normal spermatogenic architecture	Mehedi <i>et al.</i> ,(2009)
Male Swiss albino mice	0.2gm/kg b.w. and 0.4gm/kg b.w	30 days	Reduced testicular weight with tubular degeneration and impaired spermatogenesis	Gautam <i>et al.</i> ,(2010)
Male Wistar rat	72 mg / kg b.w.	60 days	Structural damage to seminiferous tubules associated with oxidative stress	Visweswaran & Krishnamoorthy (2012)
Wistar rat (<i>Rattus norvegicus</i>)	1% Tartrazine (2cc),	60 days	Degeneration and vacuolation of germinal epithelium with disrupted spermatogenic layers	Hoseinpouran <i>et al.</i> ,(2015)
Wistar rat (<i>Rattus norvegicus</i>)	300mg/kg b. w	30 days	Disturbed seminiferous tubule organization and impaired spermatogenic progression	Boussada <i>et al.</i> ,(2017)
Male Albino rat (<i>Rattus norvegicus</i>)	10mg/kg b. w. Tartrazine	8 weeks	Spermatogenic arrest with degeneration of seminiferous epithelium	Al-Seeni <i>et al.</i> ,(2018)
Male Albino rat (<i>Rattus norvegicus</i>)	7.5mg/kg b.w.	Three phases lasting 30,60,90 days	Vacuolation of seminiferous tubules, loss of Leydig cells, and distorted interstitial tissue	Elekima & Nwachuku (2019)
Male Albino rat (<i>Rattus norvegicus</i>)	100, 300,500mg/kg b.w.	60 days	Germ cell depletion, tubular shrinkage, and disrupted interstitial spaces	Meghapriya & Kishori (2019)
Male Albino rat (<i>Rattus norvegicus</i>)	Tartrazine+ sulfonic acid,	8weeks	Arrested spermatogenesis with degeneration of seminiferous tubules and interstitial tissue	El-Rabey <i>et al.</i> ,(2019)
Wistar rat (<i>Rattus norvegicus</i>)	diseased control (Tartrazine), treated group	-	Disorganization of seminiferous tubules and reduced spermatogenic activities	Mumbarddi & Savalagimath (2020)
Male Swiss albino rat (<i>Rattus norvegicus</i>)	100mg/kg b.w. 200 mg/ kg b.w. Tartrazine	72 days	Altered tubular morphology and reduced testicular mass	Meena and Meena (2020)
Male Wistar rat (<i>Rattus norvegicus</i>)	Tz at 2.5,5,10 and 20mg/kg b.w	23 days	Structural deterioration of seminiferous tubules with inflammatory responses and impaired spermatogenesis	Wopara <i>et al.</i> ,(2021)
Male and female mice	10mug/ g b.w.	30 days	Severe atrophy of seminiferous tubules,	Ara <i>et al.</i> ,(2022)

(<i>Mus musculus</i>)			vacant lumens, azoospermia, and interstitial hypoplasia	
Male Wistar rat (<i>Rattus norvegicus</i>)	300mg / kg bw.	56days	Degeneration of seminiferous tubules with increased DNA damage and impaired histoarchitecture	Hanna <i>et al.</i> ,(2023)
Male Wistar rat (<i>Rattus norvegicus</i>)	Tartrazine at 30mg/ kg b.w.	30 days	Interstitial edema, vascular congestion, tubular dilation, fibrosis, and arrested spermatogenesis	Waly <i>et al.</i> ,(2024)
Male Albino rat (<i>Rattus norvegicus</i>)	100, 250,500mg / kg b.w.	28days	Dose-dependent necrosis and atrophy of seminiferous tubules	Shok <i>et al.</i> ,(2024)
Male rat (<i>Rattus norvegicus</i>)	10 and 20 mg/ kg b.w.	30 and 60 days	Dose- and time-dependent degeneration of germ cells with seminiferous tubule disruption	Ibrahim <i>et al.</i> ,(2024)
Male rat (<i>Rattus norvegicus</i>)	Tz at 7.5mg/ kg b.w.	28 days	Pronounced vacuolation, necrotic germ cells, and disorganized spermatogenic layers	Essawy <i>et al.</i> ,(2024)
Male rat (<i>Rattus norvegicus</i>)	500mg/ kg b.w. Tartrazine	60 days	Severe disorganization of testicular architecture and damaged seminiferous tubules	Kishori & Sainath (2025)
Male rat (<i>Rattus norvegicus</i>)	100 to 400 mg/ kg b.w.	3. Months	Reduced sperm density and compromised seminiferous tubule integrity	Abdella <i>et al.</i> ,(2025)
Male rat (<i>Rattus norvegicus</i>)	7.5 mg/ kg bw.	From 5 th days of pregnancy	Reduced seminiferous tubule number, germinal epithelium vacuolation, hemorrhagic areas, and Leydig cell degeneration	Bassit & Ismael (2025)

Effects of Tartrazine on biochemical parameters

Biochemical investigations provide compelling evidence that tartrazine induces profound oxidative and endocrine disturbances in testicular tissue, which closely correlate with the histopathological damage observed in experimental models. One of the most consistently reported biochemical effects is the induction of oxidative stress, characterized by elevated lipid peroxidation and depletion of endogenous antioxidant defenses. Early studies demonstrated significant increases in malondialdehyde levels along with marked reductions in key antioxidant enzymes, including superoxide dismutase, catalase, glutathione peroxidase, and reduced glutathione, indicating impaired redox homeostasis in the testes (Visweswaran & Krishnamoorthy, 2012; Hoseinpouran *et al.*,2015) [34, 18]. These findings were repeatedly confirmed following chronic tartrazine exposure, suggesting sustained oxidative injury to testicular cells (Boussada *et al.*,2017; El-Rabey *et al.*,2019) [8, 11].

In addition to oxidative imbalance, tartrazine exposure significantly disrupts testicular enzymatic activity, reflecting compromised spermatogenesis and steroidogenesis. Altered activities of metabolic and steroidogenic enzymes such as lactate dehydrogenase, acid phosphatase, alkaline phosphatase, and 17β-hydroxysteroid dehydrogenase have been reported, highlighting impaired germ cell metabolism and androgen biosynthesis (Meena & Meena, 2020) [24]. Alterations in the nitric oxide production, total antioxidant capacity, serum proteins, and cholesterol content further indicate broad metabolic and biochemical dysregulation

induced by tartrazine (Al-Seeni *et al.*,2018; Ara *et al.*,2022) [4, 6].

Endocrine disruption is another critical biochemical hallmark of tartrazine toxicity. Numerous studies documented significant reductions in serum testosterone levels, suggesting impaired Leydig cell steroidogenic function (Elekima & Nwachuku, 2019) [12]. These changes were often accompanied by disturbances in pituitary gonadotropins, including follicle-stimulating hormone and luteinizing hormone, indicating dysregulation of the hypothalamic–pituitary–gonadal axis (Meghapriya & Kishori, 2019; Wopara *et al.*,2021) [25, 36]. Such hormonal imbalances directly contribute to impaired spermatogenesis and reduced reproductive capacity.

Recent studies have demonstrated tartrazine induced alteration in the biochemical profile by elevated levels of inflammatory mediators, increased apoptotic enzyme activity, and enhanced collagen deposition, linking oxidative stress to inflammation-driven tissue remodeling and germ cell loss (Essawy *et al.*,2024; Waly *et al.*,2024) [13, 35]. Dose- and duration-dependent declines in antioxidant enzymes, testosterone levels, and metabolic enzyme activities have been consistently reported, emphasizing the cumulative nature of tartrazine-induced biochemical damage (Ibrahim *et al.*,2024) [19]. Experimental models involving diabetes and developmental exposure further revealed susceptibility of the testes, with marked oxidative imbalance, altered steroidogenic enzymes, and increased apoptotic markers in both adult and offspring testes (Bassit & Ismael, 2025) [7].

Table 2: Effects of Tartrazine on Biochemical Parameters

Model organisms	Dose	Duration	Biochemical and hormonal Changes	Reference
Male Wistar rat	72mg/kg b.w.	60 days	Increased lipid peroxidation with depletion of antioxidant enzymes including superoxide dismutase, catalase, glutathione peroxidase, and reduced glutathione in testicular tissues	Visweswaran & Krishnamoorthy (2012)
Wistar rat (<i>Rattus norvegicus</i>)	1% Tartrazine (2cc)	60 days	Elevated nitric oxide production and lipid peroxidation with reduced glutathione content in testes	Hoseinpouran <i>et al.</i> ,(2015)
Wistar rat (<i>Rattus norvegicus</i>)	300mg/kg b.w.	30 days	Increased malondialdehyde levels with reduced antioxidant enzyme activities following chronic tartrazine exposure	Boussada <i>et al.</i> ,(2017)

Male Albino rat (<i>Rattus norvegicus</i>)	10mg/kg b. w.	8 weeks	Altered serum protein levels, cholesterol content, and antioxidant enzyme activities indicating metabolic and endocrine disturbances	Al-Seeni <i>et al.</i> ,(2018)
Male Albino rat (<i>Rattus norvegicus</i>)	Tartrazine+ sulfonic acid	8 weeks	Decreased catalase and glutathione activity accompanied by increased lipid peroxidation in testicular tissue	El-Rabey <i>et al.</i> ,(2019)
Male Albino rat (<i>Rattus norvegicus</i>)	7.5mg/kg b. w	Three phases lasting 30,60,90 days	Significant reduction in serum testosterone levels indicating impaired Leydig cell steroidogenic function	Elekima & Nwachuku (2019)
Male Albino rat (<i>Rattus norvegicus</i>)	100, 300, 500mg/ kg b. w	60 days	Decreased testosterone with disturbed luteinizing hormone and follicle-stimulating hormone levels	Meghapriya & Kishori (2019)
Male Swiss albino rat (<i>Rattus norvegicus</i>)	100mg/kg b.w. 200 mg/ kg b.w. Tartrazine	72 days	Altered activities of lactate dehydrogenase, acid phosphatase, alkaline phosphatase, and 17 β -hydroxysteroid dehydrogenase reflecting impaired spermatogenesis and steroidogenesis	Meena & Meena (2020)
Male Wistar rat (<i>Rattus norvegicus</i>)	2.5,5,10 and 20mg/kg b.w	23 days	Disruption of the hypothalamic–pituitary–gonadal axis with reduced serum FSH, LH, and testosterone levels	Wopara <i>et al.</i> ,(2021)
Male and female mice (<i>Mus musculus</i>)	Tartrazine at 10mg/ g b.w.	30 days	Decreased total antioxidant capacity along with suppressed testosterone concentration	Ara <i>et al.</i> ,(2022)
Male Wistar rat (<i>Rattus norvegicus</i>)	300mg / kg bw.	56 days	Reduced testosterone and increased oxidative biomarkers, effects reversed by stevia extract supplementation	Hanna <i>et al.</i> ,(2023)
Male Wistar rat (<i>Rattus norvegicus</i>)	30mg/ kg b.w.	30 days	Pronounced elevation of oxidative stress markers with suppression of reproductive hormones and antioxidant enzymes	Waly <i>et al.</i> ,(2024)
Male rat (<i>Rattus norvegicus</i>)	10 and 20 mg/ kg b.w.	30 and 60 days	Dose- and duration-dependent reductions in testosterone, antioxidant enzymes, and metabolic enzyme activities	Ibrahim <i>et al.</i> ,(2024)
Male Wistar rat (<i>Rattus norvegicus</i>)	at 7.5mg/ kg b.w.	28 days	Elevated inflammatory mediators and apoptotic enzyme activity with reduced reproductive hormone levels	Essawy <i>et al.</i> ,(2024)
Male rat (<i>Rattus norvegicus</i>)	Control Injected with streptozotocin, 500mg/ kg b.w. Tartrazine	60 days	Alterations in steroidogenic enzymes and oxidative stress markers confirming biochemical susceptibility of testes	Kishori & Sainath (2025)
Male rat (<i>Rattus norvegicus</i>)	100-400 mg/ kg b.w.	3 months	Restoration of antioxidant enzyme activities, testosterone levels, and metabolic enzymes following antioxidant intervention	Abdella <i>et al.</i> ,(2025)
Male rat (<i>Rattus norvegicus</i>)	Contro 7.5 mg/ kg bw.	From 5 th days of pregnancy	Altered biochemical homeostasis, oxidative imbalance, and increased apoptotic markers in offspring testes	Bassit & Ismael (2025)

Ameliorative and Protective Effects Against Tartrazine-Induced Testicular Toxicity

The amelioration of toxicant impacts involves various strategies, primarily focusing on reducing exposure, enhancing the body's natural detoxification processes, and medical interventions like chelation therapy. Many of these strategies involve the use of antioxidants and specific micronutrients to counteract oxidative stress, a primary mechanism of toxic damage. Antioxidant-based interventions effectively mitigate tartrazine-induced testicular toxicity through modulation of oxidative stress, endocrine balance, and cellular survival pathways (Hegazy *et al.*,2023) [17].

Onion extract markedly improved antioxidant enzyme activities, reduced lipid peroxidation, restored testosterone levels, and improved spermatogenic architecture in tartrazine-treated rats (Hoseinpouran *et al.*,2015) [18]. *Nigella sativa* oil supplementation significantly attenuated oxidative stress, normalized reproductive hormone levels, and preserved seminiferous tubule organization disrupted by tartrazine exposure (Al-Seeni *et al.*,2018) [3]. El-Rabey *et al.*,(2019) [4, 11] demonstrated honey administration effectively reversed tartrazine-induced oxidative damage,

improved hormonal imbalance, and restored normal testicular histology.

Herbal formulations such as Dooshivishari agada promoted recovery of spermatogenic layers and seminiferous tubule integrity following tartrazine-induced toxicity (Mumbarddi & Savalagimath, 2020) [27]. Ibrahim *et al.*,(2024) [19] observed that curcumin co-treatment significantly reduced oxidative stress markers, normalized antioxidant enzyme activity, and improved testosterone levels in rats exposed to tartrazine. Hanna *et al.* (2023) [16] further demonstrated that *Stevia rebaudiana* extract restored testosterone levels, improved antioxidant status, normalized CREM protein expression, and enhanced sperm quality in tartrazine-treated rats. Further, gallic acid supplementation effectively reduced fibrosis, oxidative stress, and hormonal disturbances while restoring testicular structure in tartrazine-treated animals (Waly *et al.*,2024) [35]. Essawy *et al.* (2024) [13] showed that *Ginkgo biloba* extracts enhanced antioxidant defenses, reduced inflammatory cytokine levels, normalized steroidogenic activity, and improved spermatogenic efficiency following tartrazine exposure. Fucoxanthin administration markedly improved sperm density, restored antioxidant enzyme activity, and preserved

seminiferous tubule integrity in tartrazine-treated rats (Abdella *et al.*, 2025) [2]. Sesame seed oil exerted protective effects against prenatal and postnatal tartrazine toxicity by

reducing apoptosis, preserving Leydig cell function, and maintaining germinal epithelium integrity in offspring testes (Bassit & Ismael, 2025) [7].

Table 3: Ameliorative and Protective Effects Against Tartrazine-Induced Testicular Toxicity

Model organisms	Dose	Duration	Ameliorative and Protective Effects	Reference
Wistar rat (<i>Rattus norvegicus</i>)	Water, 1% Tartrazine (2cc), 1% Tartrazine (2cc) + onion juice (3cc), Onion juice	60 days	Onion extracts improved antioxidant enzyme activities, reduced lipid peroxidation, restored testosterone levels, and improved spermatogenic architecture in tartrazine-treated testes	Hoseinpouran <i>et al.</i> , (2015)
Male Albino rat (<i>Rattus norvegicus</i>)	Control, 10mg/kg b. w Tartrazine, Tartrazine+Nigella sativa oil	8 weeks	<i>Nigella sativa</i> oil attenuated oxidative stress, normalized reproductive hormone levels, and preserved seminiferous tubule organization	Al-Seeni <i>et al.</i> , (2018)
Wistar rat (<i>Rattus norvegicus</i>)	diseased control (Tartrazine), treated group (Tartrazine+ DVA), auto recovery group (Tartrazine)	88 days	Dooshivishari Agada promoted recovery of spermatogenic layers and restored seminiferous tubule integrity following tartrazine toxicity	Mumbarddi & Savalagimath (2020)
Male Wistar rat (<i>Rattus norvegicus</i>)	<i>Stevia</i> extract at 1000mg/ kg b.w. Tartrazine at 300mg / kg bw. Tz+SE	56 days	<i>Stevia rebaudiana</i> extract restored testosterone levels, improved antioxidant status, normalized CREM protein expression, and enhanced sperm quality	Hanna <i>et al.</i> , (2023)
Male rat (<i>Rattus norvegicus</i>)	Tartrazine at 10 and 20 mg/ kg b.w. curcumin at 50 mg/ kg b.w 10mg/kg tz+curcumin 20mg/kg tz +curcumin	30 and 60 days	Curcumin co-treatment reduced oxidative stress, normalized enzymatic activity, and improved testosterone levels	Ibrahim <i>et al.</i> , (2024)
Male Wistar rat (<i>Rattus norvegicus</i>)	Tartrazine at 30mg/ kg b.w. Tz+ GA at 200mg / kg b.w.	30 days	Gallic acid supplementation reduced fibrosis, oxidative stress, and hormonal disturbances while restoring testicular structure	Waly <i>et al.</i> , (2024)
Male Wistar rat (<i>Rattus norvegicus</i>)	<i>Ginkgo biloba</i> at 100mg/ kg b.w. Tz at 7.5mg/ kg b.w. Tz+ EGb	28 days	<i>Ginkgo biloba</i> extracts enhanced antioxidant defenses, reduced inflammatory cytokines, normalized steroidogenic activity, and improved spermatogenic efficiency	Essawy <i>et al.</i> , (2024)
Male rat (<i>Rattus norvegicus</i>)	Fucoxanthin 100-400 mg/kg b.w.	3 months	Fucoxanthin improved sperm density, restored antioxidant enzyme activity, and preserved seminiferous tubule integrity	Abdella <i>et al.</i> , (2025)
Male rat (<i>Rattus norvegicus</i>)	7.5 mg/ kg bw. tartrazine Tz + sesame oil 5ml/ kg bw.	From 5 th days of pregnancy	Sesame seed oil protected against prenatal and postnatal tartrazine toxicity by reducing apoptosis, preserving Leydig cell function, and maintaining germinal epithelium integrity in offspring testes	Bassit & Ismael (2025)

Effects of Tartrazine on molecular parameters

Toxicants disrupt cellular function by damaging macromolecules (DNA, proteins, lipids), generating oxidative stress (ROS), interfering with cell signaling pathways, and overwhelming cellular defenses, leading to altered gene expression, enzyme dysfunction, membrane damage, organ failure, and diseases like cancer or neurological disorders, with effects varying by dose, exposure time, and the specific chemical's target within the cell (like mitochondria or receptors). Tartrazine exposure has been shown to disrupt critical signaling pathways regulating apoptosis, inflammation, cell proliferation, and steroidogenesis in testicular tissue. A consistent molecular hallmark of tartrazine toxicity is the activation of apoptotic pathways, as evidenced by increased expression and immunoreactivity of pro-apoptotic markers such as caspase-3, along with enhanced DNA fragmentation in germ cells, indicating apoptosis-mediated loss of spermatogenic cells (Hanna *et al.*, 2023; Waly *et al.*, 2024) [16, 35]. Tartrazine exposure also elicits a pronounced pro-inflammatory

molecular response, characterized by upregulation of cytokines including tumor necrosis factor- α , interleukin-1 β , and interleukin-6. This inflammatory milieu contributes to testicular tissue injury, disruption of the seminiferous epithelium, and impairment of spermatogenesis (Essawy *et al.*, 2024) [13]. Chronic inflammation, in combination with oxidative stress, exacerbates cellular damage and accelerates apoptotic processes within the testes.

In addition to apoptotic and inflammatory signaling, tartrazine significantly interferes with hormone receptor and transcriptional regulation essential for spermatogenesis. Downregulation of androgen receptor and follicle-stimulating hormone receptor expression has been reported, indicating compromised responsiveness of testicular cells to endocrine signals required for normal germ cell development and maturation (Wopara *et al.*, 2021) [36]. Furthermore, suppression of cAMP response element modulator (CREM), a key transcription factor governing post-meiotic gene expression, leads to defective sperm differentiation and maturation (Hanna *et al.*, 2023) [16]. These

molecular alterations align with the consistently reported decline in circulating testosterone levels following tartrazine exposure.

Study from Ibrahim *et al.*,(2024) [19] documented oxidative DNA damage and altered expression of genes involved in cell survival, proliferation, and apoptosis, reinforcing the genotoxic and cytotoxic potential of chronic tartrazine

intake. Developmental exposure models demonstrated that prenatal and postnatal tartrazine exposure induces persistent molecular changes, including heightened apoptotic signaling and disrupted regulatory pathways, ultimately impairing normal testicular development in offspring (Bassit & Ismael, 2025) [7].

Table 4: Molecular and Gene Expression Changes in Testes Induced by Tartrazine

Model organisms	Dose	Duration	Molecular and Gene Expression Changes	Reference
Male Wistar rat (<i>Rattus norvegicus</i>)	2.5,5,10 and 20mg/kg b.w	23 days	Downregulation of androgen receptor and follicle-stimulating hormone receptor expression indicating impaired hormonal signaling and spermatogenic regulation	Wopara <i>et al.</i> ,(2021)
Male Wistar rat (<i>Rattus norvegicus</i>)	300mg / kg bw.	56 days	Increased expression of pro-apoptotic marker caspase-3 with enhanced DNA fragmentation, indicating germ cell apoptosis	Hanna <i>et al.</i> ,(2023)
Male rat (<i>Rattus norvegicus</i>)	7.5mg/ kg b.w.	28 days	Upregulation of pro-inflammatory cytokines including TNF- α , IL-1 β , and IL-6 contributing to inflammatory testicular injury	Essawy <i>et al.</i> ,(2024)
Male rat (<i>Rattus norvegicus</i>)	10 and 20 mg/ kg b.w.	30 and 60 days	Increased oxidative DNA damage with altered expression of genes involved in cell proliferation and survival	Ibrahim <i>et al.</i> ,(2024)
Male Wistar rat (<i>Rattus norvegicus</i>)	30mg/ kg b.w.	30 days	Elevated caspase-3 immunoreactivity with reduced PCNA-positive cells confirming enhanced apoptosis and suppressed cellular proliferation	Waly <i>et al.</i> ,(2024)
Male rat (<i>Rattus norvegicus</i>)	500mg/ kg b.w.	60 days	Reduced expression of steroidogenic acute regulatory protein impairing cholesterol transport and testosterone biosynthesis in Leydig cells	Kishori & Sainath (2025)
Male rat (<i>Rattus norvegicus</i>)	7.5 mg/ kg bw.	From 5 th days of pregnancy	Prenatal and postnatal exposure induced molecular alterations associated with increased apoptotic signaling and impaired testicular development in offspring	Bassit & Ismael (2025)
Male rat (<i>Rattus norvegicus</i>)	100- 400 mg/ kg b. w	3 months	Antioxidant intervention reversed molecular disruptions by suppressing apoptotic pathways, downregulating inflammatory mediators, and restoring steroidogenic and spermatogenic gene expression	Abdella <i>et al.</i> ,(2025)

Conclusion

Tartrazine exposure induces marked testicular toxicity primarily by disrupting oxidative balance, hormonal regulation, and spermatogenesis. It increases oxidative stress and lipid peroxidation while reducing antioxidant enzymes such as SOD, CAT, and GPx, leading to biochemical imbalance. Tartrazine also impairs hormonal homeostasis by lowering testosterone levels and altering steroidogenic enzymes, including StAR and 3 β -HSD. At the molecular level, it modulates the expression of spermatogenesis- and apoptosis-related markers (CREM, Bcl-2, Bax, and caspases), resulting in increased germ cell apoptosis. These alterations cause structural damage to seminiferous tubules, dysfunction of Leydig and Sertoli cells, abnormal spermatogenesis, and reduced sperm quality and count. Antioxidant interventions effectively mitigate these effects by restoring redox balance, endocrine function, and testicular architecture, highlighting oxidative stress as the central mechanism of tartrazine-induced reproductive toxicity. Overall, available evidence identifies tartrazine as a potential male reproductive toxicant, warranting cautious consumption and further long-term mechanistic studies to assess its safety in humans.

Reference

1. Abbas JR, Al-Hamadawi HA. Effect of chocolate brown HT E155 on some hormones in male albino rats. *EurAsian Journal of BioSciences*,2019;13(1):485-489.
2. Abdella FI, Alreshidi MA, Alanazia TY, Alshammari HK, Al-Enazy HDA, Hamden K. Fucoxanthin extraction, characterization, and protective effects against tartrazine-induced oxidative, inflammatory, and

histological sperm damage in rats. *Food Bioscience*,2025, 107356.

3. Ali FA, Abdelgayed SS, El-Tawil SO, Bakeer MA. Toxicological and histopathological studies on the effect of tartrazine in male albino rats. *Int. J Biol. Biomol. Agric. Food Biotechnol. Eng*,2016;10:491-496.
4. Al-Seeni MN, El Rabey HA, Al-Hamed AM, Zamazami MA. Nigella sativa oil protects against tartrazine toxicity in male rats. *Toxicology reports*,2018;5:146-155.
5. Amin KA, Abdel-Hameid H, Abd Elsttar AH. Effect of food azo dyes tartrazine and carmoisine on biochemical parameters related to renal, hepatic function and oxidative stress biomarkers in young male rats. *Journal of Food and Chemical Toxicology*,2010;48(10):2994-2999.
6. Ara C, Arshad A, Faheem M, Khan M, Shakir HA. Protective Potential of Aqueous Extract of *Allium cepa* against Tartrazine Induced Reproductive Toxicity. *Pakistan veterinary journal*, 2022, 42(3).
7. Bassit AS, Ismael ZM. Effect of Prenatal Exposure to Tartrazine on the Postnatal Development of Gonads in Albino Rats and Protective Role of Sesame Seed Oil. *Egyptian Journal of Histology*,2025;48(2):728-739.
8. Boussada M, Lamine JA, Bini I, Abidi N, Lasrem M, El-Fazaa S, *et al.* Assessment of a sub-chronic consumption of tartrazine (E102) on sperm and oxidative stress features in Wistar rat. *International food research journal*, 2017, 24(4).
9. Chen Z. Fundamentals of toxicology: Analyzing mechanisms, assessments, and impacts of toxic substances. *Journal of Clinical*

- Toxicology,2024;14:572. <https://doi.org/10.35248/2161-0495.24.14.572>.
10. Elbanna K, Sarhan OM, Khider M, Elmogy M, Abulreesh HH, Shaaban MR. Microbiological, histological, and biochemical evidence for the adverse effects of food azo dyes on rats. *Journal of food and drug analysis*,2017;25(3):667-680.
 11. El Rabey HA, Al-Seeni MN, Al-Sieni AI, Al-Hamed AM, Zamzami MA, Almutairi FM. Honey attenuates the toxic effects of the low dose of tartrazine in male rats. *Journal of food biochemistry*,2019;43(4):1-11.
 12. Elekima I, Nwachuku OE. Evaluation of acute and chronic toxicity of tartrazine (E102) on steroid reproductive hormones of albino rats. *Asian Journal of Research and Reports in Endocrinology*,2019;2(1):5-19.
 13. Essawy A, Matar S, Mohamed N, Abdel-Wahab W, Abdou H. Ginkgo biloba extract protects against tartrazine-induced testicular toxicity in rats: involvement of antioxidant, anti-inflammatory, and anti-apoptotic mechanisms. *Environmental Science and Pollution Research*,2024;31(10):15065-15077.
 14. Gao Y, Li C, Shen J, Yin H, An X, Jin H. Effect of food azo dye tartrazine on learning and memory functions in mice and rats, and the possible mechanisms involved. *Journal of Food Science*,2011;76(6):125-129.
 15. Gautam D, Sharma G, Goyal RP. Evaluation of toxic impact of tartrazine on male Swiss albino mice. *Pharmacologyonline*,2010;1:133-140.
 16. Hanna DH, Beshay SN, El Shafee E, El-Rahman HAA. The protective effect of aqueous extract of *Stevia rebaudiana* against tartrazine toxicity in male Wistar rat. *Cell Biochemistry and Function*,2023;41(8):1462-1476.
 17. Hegazy AA, Abdel Haliem WAHR, El-Bestawy EM, Ali GME. Brief overview about tartrazine effects on health. *Eur. Chem. Bull*,2023;12:4698-4707.
 18. Hoseinpouran M, Khaki A, Nazem H. Assessment of antioxidant properties of allium cepa on serum antioxidants and spermatogenesis after consuming tartrazine in rat. *Crescent Journal of Medical and Biological Sciences*,2015;2(4):125-129.
 19. Ibrahim LI, Diab MS, Mohamed SH. Prophylactic Effect of Curcumin Against Long-Term and High-Dose Tartrazine-Induced Structural, Biochemical, and Genetic Alteration in Male Rats. *Egyptian Academic Journal of Biological Sciences. C, Physiology and Molecular Biology*,2024;16(1):365-386.
 20. Kaya SI, Cetinkaya A, Ozkan SA. Latest advances on the nanomaterials-based electrochemical analysis of azo toxic dyes Sunset Yellow and Tartrazine in food samples. *Food and Chemical Toxicology*,2021;156:112524.
 21. Khayyat L, Essawy A, Sorour J, Soffar A. Tartrazine induces structural and functional aberrations and genotoxic effects *in vivo*. *PeerJ*,2017;5:e3041.
 22. Lipskikh OI, Korotkova EI, Khristunova YP, Berek J, Kratochvil BJE. Sensors for voltammetric determination of food azo dyes-A critical review. *Electrochimica Acta*,2018;260:974-985.
 23. Martinot E, Baptissart M, Sédes L, Volle DH. Role of epigenetics in testicular cancer. *Academic Press*, 2018, 31-57. <https://doi.org/10.1016/B978-0-12-809552-2.00002-4>
 24. Meena G, Meena B. A Biochemical Study of Food Dye Tartrazine, Its effects on Swiss Albino Mice. *Kidney (g)*,2020;15:16-60.
 25. Meghapriya A, Kishori B. Tartrazine, a male reproductive suppressor in adult albino rats. *Int J Life Sci Res*,2019;7(3):1-10.
 26. Mehedi N, Ainad-Tabet S, Mokrane N, Addou S, Zaoui C, Kheroua O, *et al.* Reproductive toxicology of tartrazine (FD and C Yellow No. 5) in Swiss albino mice. *American Journal of Pharmacology and Toxicology*,2009;4(4):130-135.
 27. Mumbarddi SS, Savalagimath MP. Evaluation of the effect of dooshivishari Agada on tartrazine induced testicular toxicity-an experimental study. *International journal of panchakarma and ayurved medicine*,2016;4(4):104-110.
 28. Nazari R, Akbari S, Naseh M, Yousufzai S, Hosseini SF, Karimi F. Protective effect of co-enzyme Q10 on testicular tissue and sperm parameters in adult male rats treated with Sunset Yellow FCF. *Asian Pacific Journal of Reproduction*,2024;13(2):80-88.
 29. Rovina K, Siddiquee S, Shaarani SM. A review of extraction and analytical methods for the determination of tartrazine (E 102) in foodstuffs. *Critical Reviews in Analytical Chemistry*,2017;47(4):309-32.
 30. Shok BZ, Amagon L, Wannang NN, Amagon KI, Okpalaeke EE, Gotep JG, *et al.* Effects of selected food dyes on the reproductive system of male albino rats. *West African Journal of Pharmacy*,2024;35(2):92-100.
 31. Sun H, Wang Y, He Y, Liu B, Mou H, Chen F, *et al.* Microalgae-derived pigments for the food industry. *Marine drugs*,2023;21(2):82.
 32. Vidal JD, Whitney KM. Morphologic manifestations of testicular and epididymal toxicity. *Spermatogenesis*,2014;4(2):e979099.
 33. Visternicu M, Săvucă A, Rarinca V, Burlui V, Plavan G, Ionescu C, *et al.* Toxicological Effects of Tartrazine Exposure: A Review of *In vitro* and Animal Studies with Human Health Implications. *Toxics*,2025;13(9):771.
 34. Visweswaran B, Krishnamoorthy G. Oxidative stress by tartrazine in the testis of Wistar rats. *Journal of Pharmacy and Biological Sciences*,2012;2(3):44-49.
 35. Waly H, Ezz El-Arab RF, Abou Khalil NS, Hassanein KM, Al-Salahy MB, Saleh SM. Gallic acid counteracts tartrazine-induced testicular dysfunction in rats: biochemical, histopathological and ultrastructural evidences. *The Journal of Basic and Applied Zoology*,2024;85(1):24.
 36. Wopara I, Modo EU, Mobisson SK, Olusegun GA, Umoren EB, Orji BO, *et al.* Synthetic Food dyes cause testicular damage via up-regulation of pro-inflammatory cytokines and down-regulation of FSH-R and TESK-1 gene expression. *JBRA Assisted Reproduction*,2021;25(3):341.