

Chemical profiling and toxicological assessment of bee product propolis from Assam, India: Implications for health and safety

Trinayan Barthakur¹, Akalesh Kumar Verma², Namram Sushindrajit Singh², Diksha Dutta¹

¹ Research Scholar, Department of Zoology, Cotton University, Assam, India

² Assistant Professor, Department of Zoology, Cotton University, Assam, India

Abstract

Propolis, a natural resinous substance produced by honeybees from diverse botanical sources, offers a myriad of therapeutic properties owing to its varied plant origins. This study focuses on propolis collected from the bio-diverse region of Assam, India, situated in the North-Eastern state. The rich biodiversity of this area suggests the presence of a diverse array of phytochemicals with potential therapeutic benefits. Our research aims to identify and analyse the phytochemicals composition of the Assam propolis sample, while also investigating its possible impact on haematological parameters and sperm toxicity primarily focussing on sub-acute toxicity study. Qualitative phytochemical screening showed high concentration of secondary metabolites like alkaloids, flavonoids, and phenols. Haematological studies revealed a stark increase in RBC count, haemoglobin, %PCV and %RDW. Although the percentage neutrophil exhibited a sharp increase, the lymphocyte population experienced a decreasing trend with respect to control. There was also an increase in ALT and AST suggesting that there may be a certain degree of hepatotoxicity. The study also showed a deviation from the normal sperm morphology in a time-dependent manner.

Keywords: Haematology, honey bee, methanolic extract, phytochemicals, propolis, sperm abnormality

Introduction

Propolis is an organic resinous blend crafted by honeybees, gathered from various plant components, including flowers and other botanical sources. The resin is mixed with wax and is used in construction and adaptation. The word propolis was taken from Greek, in which the word *pro* stand for "in gateway of" and *polis* for "the city", which means propolis is used for hive defence (Vassya S. Bankova, Solange L. DE Castro, 2000)^[1]. Another name of propolis is sometime called as bee glue. It is synthesized by honey bees from products collected in the buds, saps and resins, mucilage, lattices and other plant sources (Forma & Brys, 2021; Zabaïou *et al.*, 2017)^{[2][3]}. The collections are mixed with bee wax generated from bee metabolism. Given its waxy consistency, honeybees utilize propolis as a form of cement to maintain stable moisture and temperature of their hive throughout the entire year. Additionally, propolis has been documented to seal crevices and open spaces within the beehive structure. Propolis samples collected from diverse sources showcase distinct physical properties (Zabaïou *et al.*, 2017)^[3]. Propolis is ambiguous in terms of source and derived from plants and animals (Iqbal *et al.*, 2019)^[4]. Based on the plant source and location, propolis has been classified into seven different types. They are – Poplar, Birch, Mediterranean, Greek, Red, Clusian and Pacific (Forma & Brys, 2021)^[2]. Naturally propolis is yellowish-brown to closely black in colour and available in resinous and wax form. Some studies have reported that propolis contains phenolic-like compounds and esters, polyphenol, different types of flavonoids, fatty acids, terpenoids, steroids, amino acids, polysaccharides, hydrocarbons and alcohols (Kasote *et al.*, 2022)^[5]

Propolis has been harnessed for its medicinal and nutritional benefits since ancient times, with historical use noted in Egypt, Greece, Rome, and various other regions (Kuropatnicki *et al.*, 2013)^[6]. Extensive reports

indicate that propolis collected from diverse geographic areas possesses a broad spectrum of medicinal properties, including anti-fungal, anti-cancer, and anti-bacterial activities. Its widespread application in human pharmacology and veterinary medicine is attributed to its antimicrobial, antiviral, immunomodulatory and antioxidant characteristics (Mahmad *et al.*, 2023; Santos *et al.*, 2020; Silva *et al.*, 2021; Zuhendri, F.; Chandrasekaran, K.; Kowacz, M.; Ravalía, M.; Kripal, K.; Fearnley, 2021)^[7, 8, 9, 10]. Propolis exhibits a versatile range of chemical constituents. Briefly, raw propolis comprise of resins (50%), waxes (30%), essential oils (10%), pollen (5%), and (5%) of various organic compounds (Ahangari *et al.*, 2018; Russo *et al.*, 2002; Vassya S. s, Solange L. DE Castro, 2000)^[11, 11, 12]. Although previously it was reported that more than 300 chemicals were found in propolis from the world over, latest reports reveal the presence of over 800 chemical compounds, showcasing a variety of phenolic acids, flavonoids, and vitamins (Huang *et al.*, 2014; Kasote *et al.*, 2022; Ożarowski & Karpiński, 2023)^[5, 13, 14]. The chemical composition of propolis is influenced by factors such as location, surrounding flora, altitude, and the season of collection (Ahangari *et al.*, 2018)^[11]. This inherent variability renders propolis samples highly versatile, a quality that has been harnessed both in traditional and modern medicine for the treatment of various diseases (Forma & Brys, 2021; Zabaïou *et al.*, 2017)^{[2][3]}. Our current study intends to explore the array of phytochemicals that can be found from propolis collected from the state of Assam, situated in the North-East of India. The North Eastern region of India has been bestowed with an extremely diverse range of flora and fauna; hence called a biodiversity hotspot (Kakati & Borah, 2023; Saikia *et al.*, 2009)^[15, 16]. Propolis collected from this region may hold key to phytochemicals carrying the possibility to be therapeutically significant against a range of disease. Hence,

it is crucial to investigate whether the examined sample exhibits any form of toxicity. Furthermore, our study aims to specifically identify potential sub-acute toxicities related to haematology and sperm morphology.

Materials and methods

1. Site of collection

In January (for 3 years 2018, 2020 and 2021), propolis was obtained from beekeepers in the village of Rani-Garbhanga Reserve Forest situated near the Ahomgaon (Betkuchi) region the Kamrup Metropolitan district in Assam. (Fig S1: Supplementary materials)

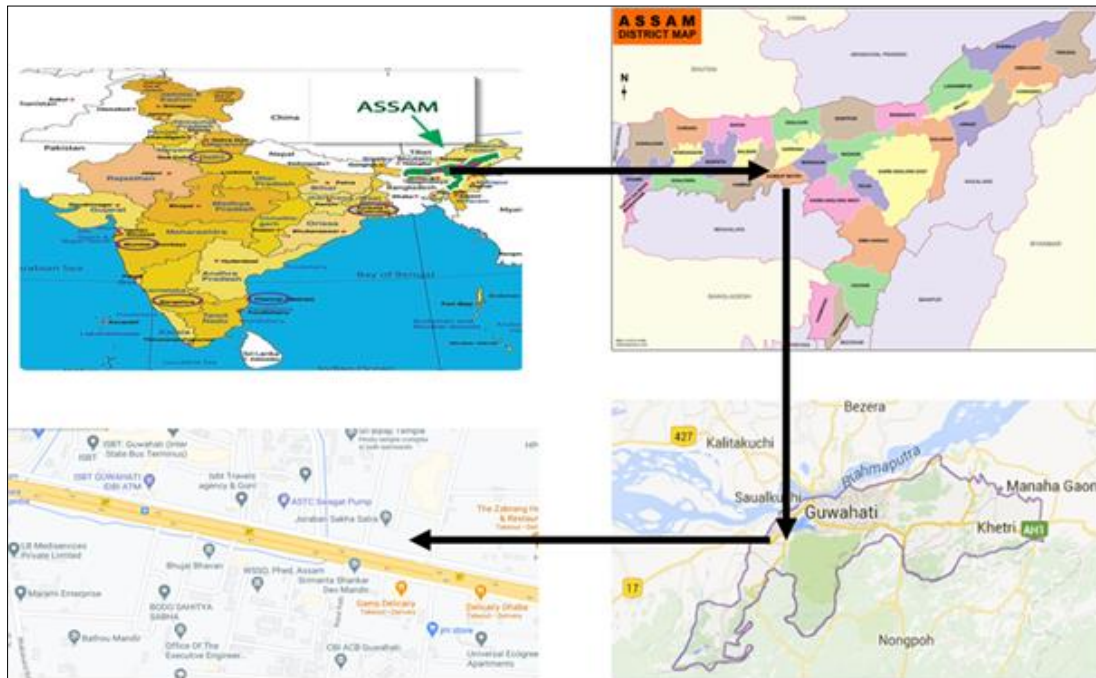


Fig S1: Study map showing the site of collection in Ahomgaon, near Rani Garbhanga Reserve forest.



Fig 1: Propolis collected from a beehive of Rani-Garbhanga, Ahomgaon, Guwahati, Assam

2. Preparation of propolis extract

After collection of bee propolis, it was shade dried for a few (6-8) days to remove moist content in it. Aqueous, methanol, ethanol, chloroform, n-hexane, n-butanol, acetone and ethyl acetate extracts was prepared according to the available methods (Muli, E. M., Maingi, J. M., Macharia, 2008) [17]. Acute toxicity study for each solvent was done experimentally using OECD guidelines 423, and it was found that the methanol extract had the highest LD₅₀ and was chosen as the solvent for experimentation. Preparation of the methanolic crude extract involved 100 grams of dried propolis dissolved in 500 ml of 70% methanol solution. The components were mixed, kept at room temperature with moderate shaking overnight. The propolis was then filtered three times, and each time it was incubated for 24 hours under room temperature. The combined filtrate was concentrated under reduced pressure by using rotatory evaporator to obtain the crude extract having yield of 12.3%. The propolis crude extract was stored in a dry and cool place.

3. Qualitative phytochemical screening of the propolis methanolic crude extract

Qualitative screening tests were performed for establishing the profiles of phytoconstituents present in the propolis crude methanolic extract. For this 0.6 gram of the propolis crude extract was dissolved in 20 ml distilled water. The analysis was done using the procedures of Harbone (1998), Kotake (1994), Kotake *et al.*, (1995), Sofowara and Odehivi (1978) and Trease and Evans (2009) [23].

4. Animal maintenance

Inbred Swiss albino mice were maintained in the laboratory under conventional conditions. They were housed in polypropylene cages having proper ventilation at room of 20 ± 2°C with free access to food pellets (Amrut Laboratory, New Delhi) and water *ad libitum*. Animals in the age group of about 10-12 weeks old of both sexes (25-30 g) were used for the experiments. The animals were obtained from the Animal House Facility of Cotton University, Guwahati, Assam. All the experiments were carried out strictly according to the CPCSEA guidelines. Animals were checked regularly for any infection.

5. Hematology and sperm abnormality

5.1. Experimental design

Acute toxicity study was done using oral administration under the OECD guideline 423, and the LD₅₀ was calculated. This study was conducted for a period of 14 days. The sub-acute toxicity assessment was done for a period of 28 days. Briefly, 3.6 grams of the propolis extract was dissolved in 120 ml of saline solution (0.89% NaCl) to constitute a stock solution. The doses in 0.25 mL of the propolis extract was administered intra-peritoneally according to the body weight of the mice. The albino mice were divided into three groups- I, II and III. Group-I was control. Group-II was 14 days treated mice and group-III was 28 days treated mice respectively. Each group consisted of 6 mice, with three males and three females. Each mice of group-II was administered with 300mg/kg body weight/day of the extract (dose) for 14 consecutive days while group- III

was administered with the same dose for 28 days consecutively. The control group was administered with the vehicle saline solution for 28 days.

5.2. Determination of LD₅₀

The acute toxicity assessment of the sample showed that the LD₅₀ of the methanolic extract exceeded 2000 mg/kg. Sub-acute toxicity assessment was done for a period of 28 days and the haematological changes and sperm abnormality were noted at a standardised dose of 300 mg/kg body weight/day.

5.3. Sperm abnormality assay

Sperms from mature male mice were sacrificed on the 14th and 28th day of treatment. The cauda epididymis was removed and placed in physiological saline solution. The cauda epididymis was minced into small pieces and kept undisturbed for 20 minutes. The spermatozoa were spread on a clean slide, air-dried, fixed in absolute methanol for 15 minutes and then stained with 1% aqueous eosin-Y and smears were made 30 minutes thereafter. Anomalies in sperm morphology were studied from each group based on the work of Wyrobek & Bruce, 1975 [24]. Each group comprised of 3 male mice.

5.4. Haematological and biochemical analysis

Blood sample for complete blood count (CBC) was drawn from the retro-orbital sinus (Fox *et al.*, 2007; Lindstrom *et al.*, 2015; Diehl *et al.*, 2001; Sullivan & Wallace, 2005) [26, 27, 28, 29]. The collected blood was placed on EDTA which was used as an anti-coagulant. All these experiments were done using autoanalyzer (CBC: BK-63005, Shandong, China). The parameters for haematological analysis includes haemoglobin, packed cell volume (PCV), RBC count, mean corpuscular haemoglobin (MCH), mean corpuscular volume (MCV), mean corpuscular haemoglobin concentration (MCHC), red cell distribution width (RDW), total leucocyte count (TLC), differential leucocyte count (neutrophils, lymphocytes, eosinophil, monocyte and basophil), and erythrocyte sedimentation rate (ESR).

The parameters for the liver function test (LFT) includes Alanine aminotransferase (ALT), serum glutamate pyruvate transaminase (SGPT), serum glutamate oxaloacetate transaminase (SGOT), alkaline phosphatase (ALP). While the parameters for biochemical analysis includes sugar, urea, creatinine, potassium (K) and sodium (Na).

6. Statistical analysis

The statistical analysis was done using Ordinary one way ANOVA followed by post-hoc Bonferroni test. A *p*-value of ≤ 0.05 was selected to indicate significant differences among groups. The software used for this purpose is Graph Pad Prism (Version 8.0.2)

Results

1. Qualitative phytochemical screening.

Phytochemical analysis reveals the presence in high quantities of alkaloid, polyphenols and flavonoids. The results of phytochemical screening have been summarized in table 1

Table 1: Qualitative Phytochemical Screening of the propolis

Serial no.	Chemical constituent	Test performed	Methanolic extract
1.	Alkaloid	Dragendorff's test	+++
		Wagner's test	+++
		Mayer's test	+++
2.	Carbohydrate	Fehling's test	+++
		Benedict's test	+++
		Molisch's test	+++
6.	Triterpenoids	Salkowski's test	-
		Liebermann-burchard's test	-
8.	Flavanoids	Alkaline reagent test	++
9.	Proteins and amino acids	Millon's test	++
		Biuret's test	+
		Ninhydrin's test	+
10.	Phytosterols	Liebermann-burchard's test	++
11.	Oils and fats	Spot test	+++
		Saponification test	+++
12.	Phenolic compound and tanins	Ferric chloride test	++
		Lead acetate test	+++
		Gelatin test	+
		Alkaline reagent test	++
13.	Gums and mucilages		++
14.	Steroids	Salkowski's test	+
		Liebermann-burchard's test	+++

2. Haematology

Haematological studies revealed a stark increase in RBC count, haemoglobin, %PCV and %RDW. Although the percentage neutrophil exhibited a sharp increase, the overall lymphocyte population experienced a decreasing trend with respect to control. There was also an increase in ALT and AST suggesting that there may be a certain degree of hepatotoxicity. Significant changes ($p < 0.0001$) in the concentration of sodium, potassium creatinine (CRTN) and sugar levels were observed between the control groups and 28 days treatment groups. There was a stark increase in

sodium, potassium and creatinine concentration, however a decline in the sugar levels were seen across different treatment groups. Significant changes were also seen among treatment groups among sodium ($p < 0.01$), potassium ($p < 0.0001$), CRTN and sugar ($p < 0.001$). No significant change however was seen in the concentrations of urea (Fig S2: Supplementary materials)

The results of haematological assay have been summarized in figures (2-4).

Biochemical Parameters

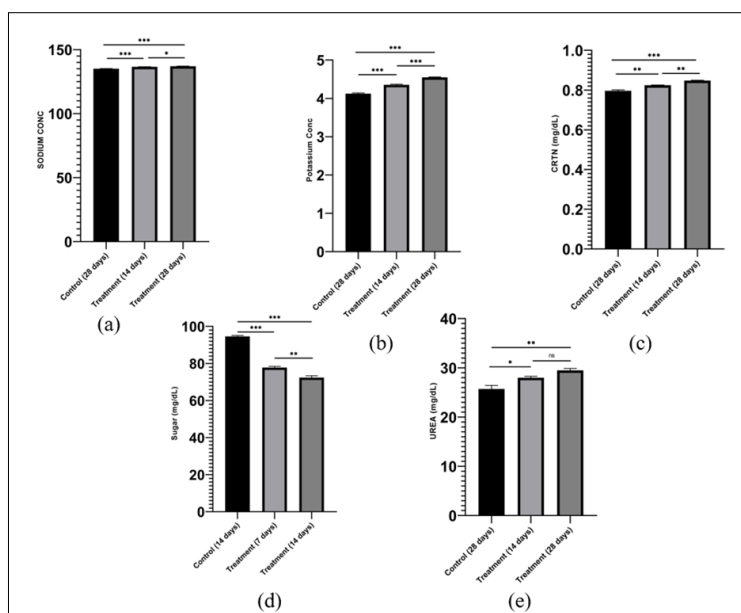


Fig S2: Haematological analysis showing different biochemical parameters. Results were obtained from ordinary One-way ANOVA and are expressed as \pm SEM, followed by post-hoc Bonferroni test; $n=6$; p value ≤ 0.05 . Significant differences represent *** $p < 0.0001$; ** $p < 0.001$; * $p < 0.01$; ns $p > 0.01$. (a) Sodium, (b) Potassium, (c) Creatinine (CRTN), (d) Sugar, (e) Urea

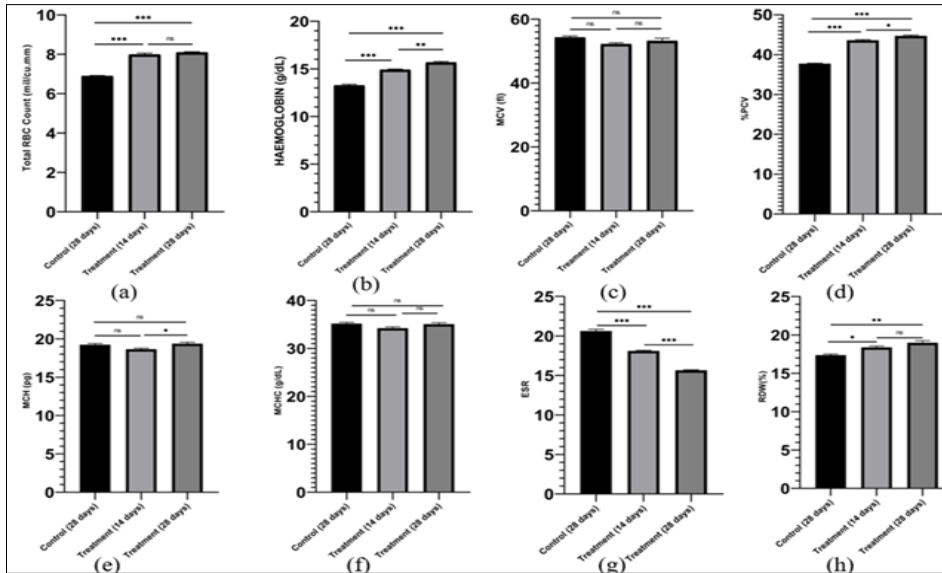


Fig 2: Haematological analysis showing changes different parameters of blood. Results were obtained from ordinary One-way ANOVA and are expressed as \pm SEM, followed by post-hoc Bonferroni test; $n=6$; p value ≤ 0.05 . Significant differences represent *** $p < 0.0001$; ** $p < 0.001$; * $p < 0.01$; ns $p > 0.01$

(a) Total RBC count (b) Haemoglobin (c) MCV (d) %PCV (Haematocrit) (e) MCH (f) MCHC (g) ESR (h) %RDW

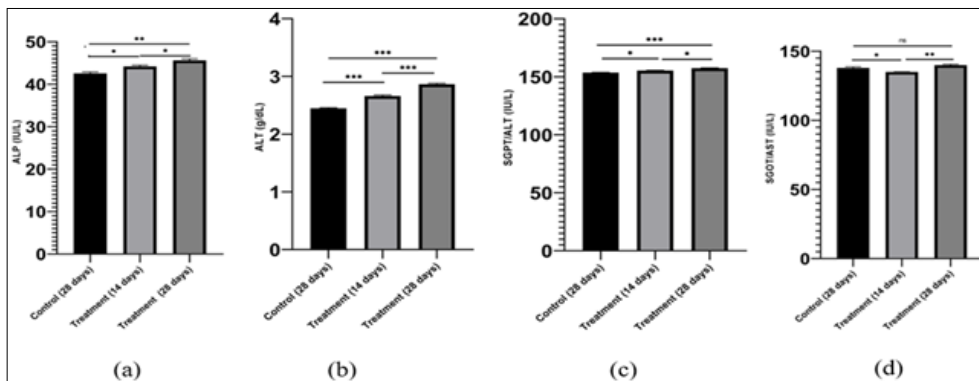


Fig 3: Haematological parameters showing different parameters of Liver Function Test (LFT). Results were obtained from ordinary One-way ANOVA and are expressed as \pm SEM, followed by post-hoc Bonferroni test; $n=6$; p value ≤ 0.05 . Significant differences represent *** $p < 0.0001$; ** $p < 0.001$; * $p < 0.01$; ns $p > 0.01$

(a) ALP (b) ALT (c) SGPT (d) SGOT/AST

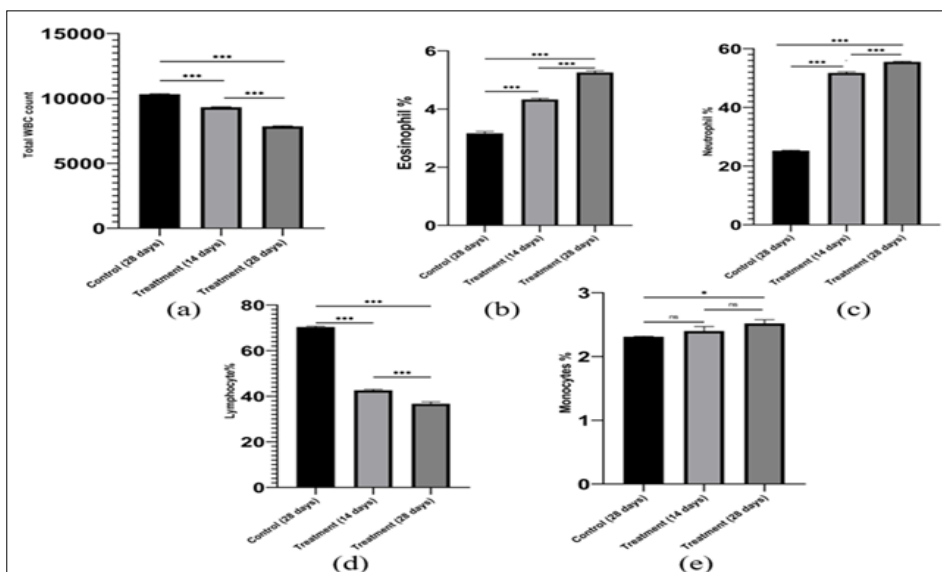


Fig 4: Haematological analysis showing different leucocyte parameters including. Results were obtained from ordinary One-way ANOVA and are expressed as \pm SEM, followed by post-hoc Bonferroni test; $n=6$; p value ≤ 0.05 . Significant differences represent *** $p < 0.0001$; ** $p < 0.001$; * $p < 0.01$; ns $p > 0.01$

(a) Total WBC (b) Eosinophil % (c) Neutrophil % (d) Lymphocyte % (e) Monocyte %

3. Sperm abnormality

The sperm abnormality assay revealed a time dependent increase of abnormal sperms in treatment groups in comparison to the control groups. A significant number of

sperms ($p < 0.0001$) exhibited an array of anomalous morphology (Fig S3: Supplementary materials). These included hook-less (HL), diffused head (DH), folded (FL) and amorphous head (AH). The results have been summarized under table 2

Percentage abnormal sperms

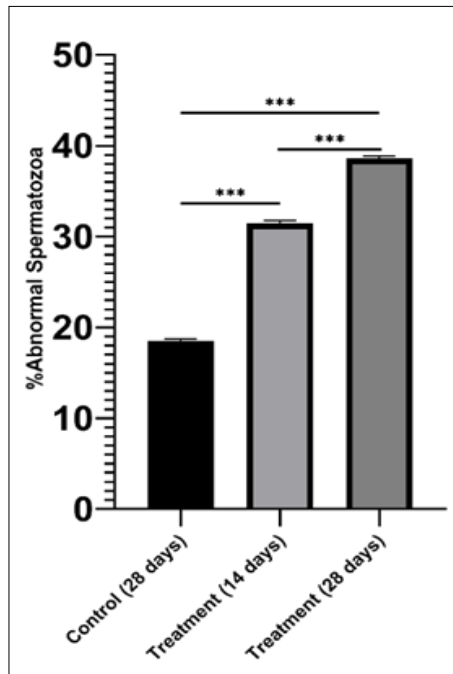


Fig S3: Deviations from the ideal sperm morphology, over the treatment period against control. Results were obtained from ordinary One-way ANOVA and are expressed as \pm SEM, followed by post-hoc Bonferroni test; $n=3$; p value ≤ 0.05 . -Significant differences represent *** $p < 0.0001$; ** $p < 0.001$; * $p < 0.01$; ns $p > 0.01$

Table 2: Sperm abnormality assay

Treatment	Total Sperms Observed	Abnormal Sperms					%Abnormal sperms
		HL	DH	FL	AH	Total	
Control	328	4	14	23	20	61	18.59756098
14-day treatment	341	15	26	45	21	107	31.37829912
28-day treatment	401	25	50	52	28	155	38.65336658

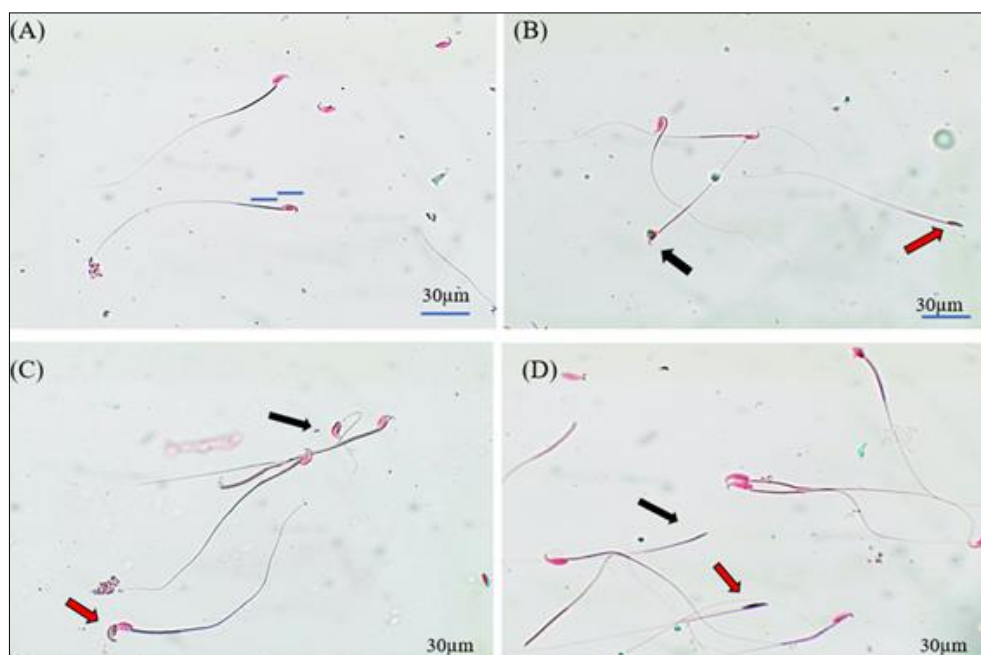


Fig 5: Illustrations showing anomalous sperm morphology

- (a) Normal sperms
 (b) Blunt Hook Sperm (blackarrow), Hookless sperm (red arrow)
 (c) Diffused head sperm (red arrow), Coiled middle piece (black arrow)
 (d) Hookless sperm (red arrow), Headless sperm (black arrow)
 Scale bar displayed is 30µm in length.

Discussions

Phytochemical screening revealed high quantities of polyphenols, flavonoids and alkaloids. This implies that the crude extract bears the potential of having antioxidant, antibacterial, anti-cancer, cardioprotective, as well as immune system promoting and anti-inflammatory effects (Abou Baker, 2022; Mir *et al.*, 2024; Panche *et al.*, 2016; Roy *et al.*, 2022; Ullah *et al.*, 2020; Yi *et al.*, 2023)^[30, 32, 33, 34, 35]. Apart from showing anti-inflammatory and antioxidant effects, polyphenols have also been reported to have protective effects against neurodegenerative disease like Alzheimer's disease, Parkinson's Disease, Huntington's Disease (Cory *et al.*, 2018; Winiarska-Mieczan *et al.*, 2023)^[36, 37]. The results open up an array of possibilities to explore the full potential of the extract. Due to rich biodiversity of North-East India, the collected propolis sample may harbour enormous therapeutic potential which must be explored further. Although propolis has been used in combination therapy to reduce sperm abnormalities, (Al-Amoudi, 2015)^[38] our study revealed the administration of propolis to have a certain degree of time dependent toxicity on the sperms. Morphological anomalies in sperm may be a function of chromosomal aberration (Bruce *et al.*, 1974)^[39]. The haematological parameters showed a significant increase in the RBC count in the treatment groups in a time dependent as compared to the control group. The rise in RBC production (polycythaemia) can be an indicator of the protective nature of flavonoids against haemolysis (Asgary *et al.*, 2005)^[40]. It can be predicted that the methanolic extract of propolis induces a regenerative state onto the RBCs and thereby it is possible to exhibit polychromasia and anisocytosis as is indicated by the rise in RDW (O'Connell *et al.*, 2015)^[41]. The rise in RBC counts was also validated by the accompanying rise in haemoglobin concentration as well as haematocrit (%PCV) levels. Ideally, the haematocrit should be thrice the haemoglobin concentration (Carneiro *et al.*, 2007; O'Connell *et al.*, 2015)^[41, 42]. The MCH, haemoglobin, and haematocrit, which are the major indices for evaluating erythrocytes (Peters *et al.*, 2011)^[43], did not exceed the normal range. There was a sharp increase in neutrophil concentration in the treatment groups when compared to the control group suggesting that the methanolic extract of propolis can contain leucopoietic and immunomodulatory activities. It was also seen that there was a stark decrease in the percentage of lymphocytes compared to the control group in a time dependent manner. Flavonoids have an immunosuppressive role in lymphoproliferation (You *et al.*, 1998)^[44]. The liver function parameters revealed that there has been a significant increase in the AST and ALT levels, which is indicative of borderline hepatotoxicity. ALT is considered as a better indicator of liver damage than AST, as the latter is not exclusively found in the liver (Fernandes *et al.*, 2018)^[45]. However, studies have shown that the rise in ALT levels may not have a direct correlation with the

severity of a patient's liver disease (Toita *et al.*, 2018)^[46]. Elevated AST, ALT and ALP levels can also be an indicator of haemolysis (Murakami & Shimizu, 2013)^[47].

Conclusion

Propolis collected from the North-Eastern state of India, harbours an array of phytochemicals which holds a very rich therapeutic potential. Based on the phytochemical profile of the propolis collected, it is safe to assume that methanolic crude extract of the sample may have antioxidant, antibacterial, anti-cancer, cardioprotective, anti-inflammatory and immunomodulatory effects. Although a small degree of toxicity was exhibited, it may not necessarily have a high biological impact. A further assessment of organ toxicity is needed to be assured of the safety of use of the sample. The results ensure that the sample can be considered safe to explore any therapeutic experimentation.

References

- Bankova V, De Castro S, Marucci M. Propolis: recent advances in chemistry and plant origin, *Apidologie*, 2000;31:3–15, doi: 10.1111/j.1475-6765.1992.tb00316.x.
- Forma E, Bryś M. Anticancer activity of propolis and its compounds. *Nutrients*, 2021;13(8):2594. doi: 10.3390/nu13082594.
- Zabaoui N. Biological properties of propolis extracts: Something new from an ancient product. *Chemistry and Physics of Lipids*, Elsevier Ireland Ltd, 2017;207:214:222. doi: 10.1016/j.chemphyslip.
- Iqbal M, Tai-ping F, Watson D, Alenezi S, Saleh K, Sahlan M. Preliminary studies: the potential anti-angiogenic activities of two Sulawesi Island (Indonesia) propolis and their chemical characterization. *Heliyon*, 2019;5(7):01978. doi: 10.1016/j.heliyon.2019.e01978.
- Kasote D, Bankova V, Viljoen AM. Propolis: chemical diversity and challenges in quality control. *Phytochemistry Reviews*, Springer Netherlands, 2022;21(6):1887–1911. doi: 10.1007/s11101-022-09816-1.
- Kuropatnicki AK, Szliszka E, Krol W. Historical aspects of propolis research in modern times. Evidence-based Complement. *Altern. Med*, 2013;2013:1–11. doi: 10.1155/2013/964149.
- Mahmad A, Chua LS, Noh TU, Siew CK, Seow LJ. Harnessing the potential of *Heterotrigena itama* propolis: An overview of antimicrobial and antioxidant properties for nanotechnology-Based delivery systems. *Biocatal. Agric. Biotechnol*, 2023;54:102946. doi: 10.1016/j.bcab.2023.102946.
- Silva H, Francisco R, Saraiva A, Francisco S, Carrascosa C, Raposo A. The cardiovascular therapeutic potential of propolis—a comprehensive review. *Biology (Basel)*, 2021;10(1):1–20. doi: 10.3390/biology10010027.
- Zulhendri JP, Chandrasekaran F, Kowacz K, Ravalía M, Kripal KK, Fearnley J, et al. Antiviral, Antibacterial, Antifungal, and Antiparasitic Properties of Propolis: A Review. *Foods*, 2021;10:1360–1389.
- Santos LM. Propolis: types, composition, biological activities, and veterinary product patent prospecting. *J. Sci. Food Agric*, 2020;100(4):1369–1382. doi: 10.1002/jsfa.10024.

11. Ahangari Z, Naseri M, Vatandoost F. Propolis: Chemical composition and its applications in endodontics. *Iran. Endod. J*,2018;13(3):285–292. doi: 10.22037/iej. V13i3.20994.
12. Russo A, Longo R, Vanella A. Antioxidant activity of propolis: role of caffeic acid phenethyl ester and galangin. *Fitoterapia*. Nov,2002;73(1):S21-S29. doi: 10.1016/S0367-326X (02)00187-9.
13. Ożarowski M, Karpiński TM. The Effects of Propolis on Viral Respiratory Diseases. *Molecules*, 2023, 28(1). doi: 10.3390/molecules28010359.
14. Huang S, Zhang CP, Wang K, Li GQ, Hu FL. Recent advances in the chemical composition of propolis. *molecules*,2014;19(12):19610–19632, doi: 10.3390/molecules191219610.
15. Saikia MK, Kalita J, Saikia PK. Ecology and conservation needs of nymphalid butterflies in disturbed tropical forest of Eastern Himalayan biodiversity hotspot, assam, India. *Int. J. Biodivers. Conserv*,2009;1(7):231–250.
16. Kakati R, Borah KJ. Status of Threatened Biodiversity in Behali Reserved Forest, 2023, 45–53.
17. Muli J, Maingi EM, Macharia JM. Antimicrobial Properties of Propolis and Honey from the Kenyan Stingless bee, *Dactylurina Schimidti*. *Apiacta*,2008;43:49-61.
18. Choudhari MK, Haghniaz R, Rajwade JM, Paknikar KM. Anticancer activity of Indian stingless bee propolis: An *in vitro* Study. Evidence-based Complement. Altern. Med, 2013. doi: 10.1155/2013/928280.
19. Harborne AJ, *Phytochemical Methods a Guide to Modern Techniques of Plant Analysis*, 3rd ed. Berlin, Germany: Springer science & business media, 1998.
20. Kokate CK. *Practical Pharmacognosy*. Vallabh Prakasan, Delhi, 1994, 107-111.
21. Kokate CK, Khandelwal KR, Pawar AP, Gohalz SB. *Practical Pharmacognosy*, 4th ed. New Delhi, India: Vallabh Prakashan, 1995.
22. OdebiyiOO, Sofowara EA. Phytochemical screening of Nigerian medicinal plants. *Lloydia*,1978;41(3):234-46. Available: <https://pubmed.ncbi.nlm.nih.gov/672462/>
23. Evans WC. *Pharmacognosy*, 16th ed. Elsevier, 2009.
24. Wyrobek AJ, Bruce WR. Chemical induction of sperm abnormalities in mice. *Proc. Natl. Acad. Sci. U. S. A*,1975;72(11):4425–4429. doi: 10.1073/pnas.72.11.4425.
25. Sørensen DB, Metzdorff SB, Jensen LK, Andersen KH, Teilmann AC, Jensen HE, et al. Time-dependent pathologic and inflammatory consequences of various blood sampling techniques in mice. *J. Am. Assoc. Lab. Anim. Sci*,2019;58(3):362–372, doi: 10.30802/AALAS-JAALAS-18-000064.
26. Lindstrom LM, Moore DM, Zimmerman K, Smith SA. Hematologic Assessment in Pet Rats, Mice, Hamsters, and Gerbils. *Blood Sample Collection and Blood Cell Identification. Veterinary Clinics of North America - Exotic Animal Practice*,2015;18(1):21–32, doi: 10.1016/j.cvex.2014.09.004.
27. Sullivan MT, Wallace EL. Blood collection and transfusion in the United States in 1999 *Transfusion*,2005;45(2):141–148. doi: 10.1111/j.1537-2995.2004. 03288. X.
28. Diehl K. A Good Practice Guide to the Administration of Substances and Removal of Blood, Including Routes and Volumes. *J Appl Toxicol*, September,2000-2001;21:15–23.
29. Fox JG, Barthold SW, Davisson MT, Newcomer CE, Quimby FW, Smith AL. *The Mouse in Biomedical Research*, 2007, 1–4(5). doi: 10.1142/9781860947162_0015.
30. Mir SA, Dar A, Hamid L, Nisar N, Malik JA, Ali T, et al. Flavonoids as promising molecules in the cancer therapy: An insight. In *Current Research in Pharmacology and Drug Discovery*,2023-2024;6:100167. Elsevier B.V. <https://doi.org/10.1016/j.crphar.2023.100167>
31. Yi X, Dong M, Guo N, Tian J, Lei P, Wang S, Yang, Y, et al. Flavonoids improve type 2 diabetes mellitus and its complications: a review. In *Frontiers in Nutrition*,2023;10:1-16. <https://doi.org/10.3389/fnut.2023.1192131>
32. Abou Baker DH. An ethnopharmacological review on the therapeutical properties of flavonoids and their mechanisms of actions: A comprehensive review based on up to date knowledge. *Toxicology Reports*, Elsevier B.V,2022;9:445–469. doi: 10.1016/j.toxrep.2022.03.011.
33. Roy A, Khan A, AhmadI Alghamdi S, Rajab BS, Babalghith AO, Alshahrani MY, et al. Flavonoids a Bioactive Compound from Medicinal Plants and Its Therapeutic Applications. In *BioMed Research International*, 2022, 9. <https://doi.org/10.1155/2022/5445291>.
34. Ullah A, Munir S, Badshah SL, Khan N, Ghani L, Poulson BG, et al. Important Flavonoids and Their Role as a Therapeutic Agent. *Molecules*,2020;25:1-39.
35. Panche AN, Diwan AD, Chandra SR. Flavonoids: Anoverview. *Journal of Nutritional Science*, 2016, 5. doi: 10.1017/jns.2016.41.
36. Winiarska Mieczan A, Kwiecień M, Jachimowicz Rogowska K, Donaldson J, Tomaszewska E, Baranowska Wójcik E. Anti-Inflammatory, Antioxidant, and Neuroprotective Effects of Polyphenols Polyphenols as an Element of Diet Therapy in Depressive Disorders. *International Journal of Molecular Sciences*, 2023, 24(3). doi: 10.3390/ijms24032258.
37. Cory H, Passarelli S, Szeto J, Tamez M, Mattei J. The Role of Polyphenols in Human Health and Food Systems: A Mini-Review. *Front. Nutr*,2018;5:1-9, doi: 10.3389/fnut.2018.00087.
38. Al Amoudi WM. Effect of Propolis on the reproductive toxicity of Deltamethrinin male albino Rats. *Anat. Physiol*,2015;5:1-7.
39. Bruce WR, Furrer R, Wyrobek AJ. Abnormalities in the shape of murine sperm after acute testicular X-irradiation. *Mutat. Res. - Fundam. Mol. Mech. Mutagen*,1974;23:3:381-386, doi: 10.1016/0027-5107(74)90112-2.
40. Asgary S, Naderi GH, Askari N. Protective effect of flavonoids against red blood cell hemolysis by free radicals. *Exp. Clin. Cardiol*,2005;10(2):88-90.
41. O’Connell KE, Mikkola AM, Stepanek AM, Vernet A, Hall CD, Sun CC, et al. Practical murine hematopathology: A comparative review and

- implications for research. In *Comparative Medicine*,2015:65(2):96-113
42. Carneiro IA, Drakeley CJ, Owusu Agyei S, Mmbando B, Chandramohan D. Haemoglobin and haematocrit: Is the threefold conversion valid for assessing anaemia in malaria-endemic settings. *malar. J*,2007:6:1–5, doi: 10.1186/1475-2875-6-67.
 43. Peters SO, Gunn HH, Imumorin IG, Agaviezor BO, Ikeobi CON. Haematological studies on frizzled and naked neck genotypes of Nigerian native chickens. *Trop. Anim. Health Prod*,2011:43(3):631-638, doi: 10.1007/s11250-010-9743-7.
 44. You KM, Son KH, Chang HW, Kang SS, Kim HP. Vitexicarpin, a flavonoid from the fruits of *Vitex rotundifolia*, inhibits mouse lymphocyte proliferation and growth of cell lines *in vitro*. *planta Med*,1998:64(6):546-550. doi: 10.1055/s-2006-957511.
 45. Fernandes DP, Pimentel MM, L Dos Santos FA, Praxedes ÉA, De Brito PD, Lima MA, *et al*. Hematological and biochemical profile of BALB/c nude and C57BL/6 SCID female mice after ovarian xenograft. *Anais Da Academia Brasileira de Ciencias*,2018:90(4):3941–3948. <https://doi.org/10.1590/0001-3765201820180586>
 46. Toita R, Kawano T, Fujita S, Murata M, Kang JH. Increased hepatic inflammation in a normal-weight mouse after long-term high-fat diet feeding. *J. Toxicol. Pathol.*,2018:31(1):43–47. doi: 10.1293/tox.2017-0038.
 47. Murakami J, Shimizu Y. Hepatic Manifestations in Hematological Disorders. *Int. J. Hepatol*,2013:2013:1-13. doi: 10.1155/2013/484903.