



Toxicity of pesticide fipronil 5% SC (Mahaveer SC) on the histology of *Oreochromis mossambicus*

N Vasanthi, K Thamarai Chelvi, K Muthukumaravel*

Department of Zoology, Khadir Mohideen College, (Bharathidasan University), Adirampattinam, Tamil Nadu, India

Abstract

Effect of fipronil on the histological changes in the gill, liver and kidney of *Oreochromis mossambicus* were studied at 10% sub lethal concentration (96 hours LC₅₀: 0.006 ppm) for 10, 20 and 30 days. Histological changes such as lamellar fusion, lamellar cell hyperplasia, degenerated secondary gill lamellae; degeneration of hepatocytes and vacuolation; Bowman's space dilation and renal tubules detachment were observed in the gill, liver and kidney respectively, during chronic exposure to fipronil.

Keywords: fipronil pesticide, tilapia fish, histology

Introduction

Pesticides induced alterations in histopathology of various fish species are extensively studied. Lawrence Ezemonye *et al.* (2010) [8] have observed various histological changes in the gill and liver of African cat fish *Clarias gariepinus* exposed to Gammalin 20. Tamil Selvi and Ilavazhahan (2012) [17] noticed changes in the gill histological structure of catla exposed to methyl parathion. Anupama and Amit Kumar Jha (2020) [2] have also reported histological changes in gill, liver and kidney tissues of *Anabas testudineus* under pesticide paraquat. Islam M. EI- Garawani have described various histological abnormalities in gill, liver and muscle tissues of *Oreochromis niloticus* exposed to neonicotinoids. Fipronil is an N-phenylpyrethroid a second generation of insecticide which is relatively new and now widely used in agriculture and to control the pests. Review of literature revealed that most of the studies are related to individual effect of organophosphate, organochlorine or pyrethroid pesticide compounds on fishes. However, the relative effects of pesticide fipronil on freshwater fish *Oreochromis mossambicus* have not been yet known. Hence, the present study has been carried out to study the effect of pesticide fipronil on histological aspects of the *Oreochromis mossambicus*.

Materials and methods

Procurement of the experimental animal

The *Oreochromis mossambicus* was collected from the Chellikurichy lake (Lat. 10° 21 N'; Long. 79° 24'E), Pudukkottai Ullur near Adirampattinam, Thanjavur, Tamil Nadu. The fishes were stocked in large cement tanks which were already washed and sterilized with potassium permanganate solution. Adult fishes, weighting about 7.5 – 9.0 g and 8.5 – 10.5 cm in length were used for the experiments. Experimental fishes were maintained in small plastic troughs. Under laboratory condition these fishes are sensitive to the accumulation of ammonia and hence the water was frequently changed. The fishes were feed with boiled egg white. The excess food and their excreta were siphoned out daily, to prevent fungal growth. The fishes were acclimatized for 30 days in freshwater medium.

Acute toxicity (LC₅₀) test

An acute toxicity (LC₅₀) test by static renewal bioassay method was conducted to determine the toxicity of fipronil in *Oreochromis mossambicus* which were exposed to various concentrations of fipronil for 96 hours. After 96 hours of exposure the data obtained was subjected to Finney's probit analysis method (Finney, 1971) [5] to determine LC₅₀ value. The concentration at which 50 % survival/mortality occurred in fipronil treated fishes was taken as the median lethal concentration (LC₅₀) for 96 hour which was 0.006 ppm. One tenth (1/10) of the LC₅₀ value was taken for the sublethal studies according to Sprague (1973) [16].

Histology Study

At the end of 10, 20 and 30 days of exposure, the gill, liver and kidney of both control and fipronil treated (10% sub lethal concentration of 96 LC₅₀) fishes were dissected and fixed in Bouin's fluid. Tissues were processed according to standard histological procedures (Humason, 1972) [6] and 6µ thick paraffin section were taken and stained with haematoxylin and counter stained with aqueous eosin. The slides were analysed and photographs were taken.

Results and discussion

Histological changes in the gill such as lamellar fusion, lamellar cell hyperplasia, degenerated secondary gill lamellae during chronic exposure to fipronil (Plate 1). The histopathological lesions of the gills of the Nile tilapia, *Oreochromis niloticus* due to chlorpyrifos toxicity were reported in detail by Mohamed Amzad Hossain *et al.* (2022) [10, 11]. They observed degeneration of gill epithelium and fusion of gill lamellae. These observations can be compared with the observations of Arumugan Stalin *et al.* (2019) [3] who have reported degeneration of gill epithelium, fusion of secondary gill lamellae and necrosis in *Channa punctatus* exposed to sublethal concentrations of chlorpyrifos. Noor S. Jaffer *et al.* (2017) [13] have also reported the gills due to chlorpyrifos toxicity in *Cyprinus carpio*.

PLATE – 1

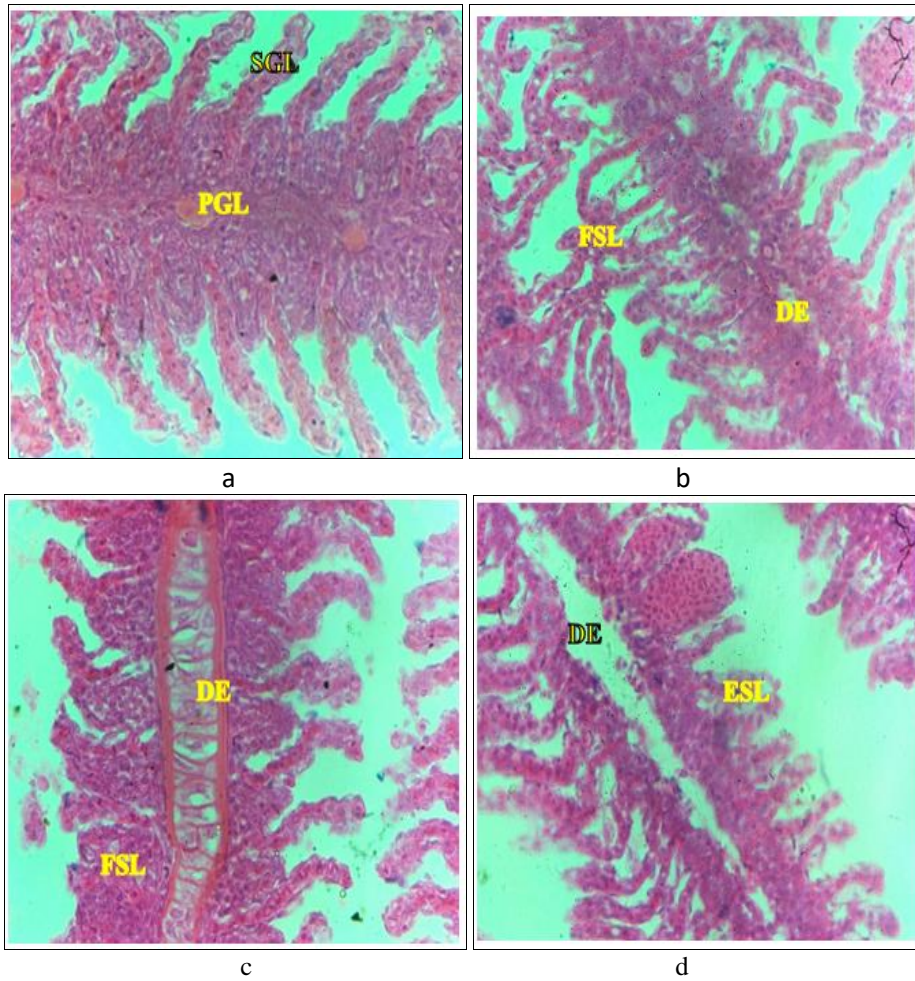


Plate 1: Histopathological lesions in the gill of *Oreochromis mossambicus* exposed to 10% sublethal concentration of fipronil at different durations

a. Control

PGL - Primary Gill Lamellae
SGL - Secondary Gill Lamellae

b. 10 days treated

FSL - Fusion of secondary lamellae
DE - Degeneration of epithelium

c. 20 days treated

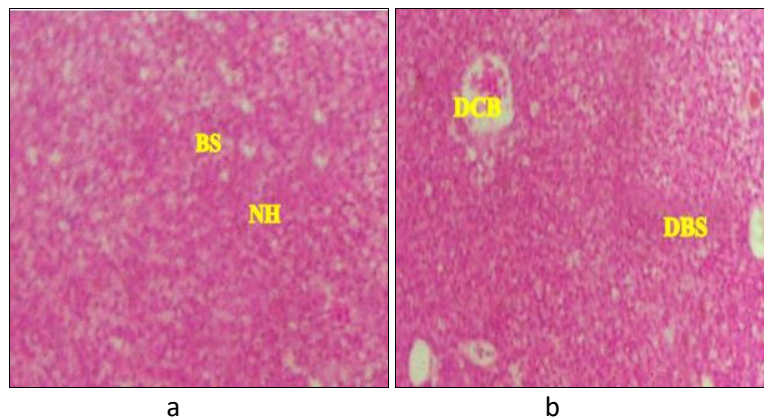
FSL - Fusion of secondary lamellae
DE - Degeneration of epithelium

d. 30 days treated

DE - Degeneration of epithelium
ESL - Erosion of secondary lamellae

In the liver of *Oreochromis mossambicus* under fipronil caused several damages including vacuolation, degeneration of hepatocytes and necrosis (Plate 2). These observations were compared with the report of Bartosz Bojarski *et al.* (2022)^[4] who have worked on the liver tissue of *Cyprinus carpio* in glyphosate herbicide toxicity. These observations correlate with the report of Lawrence Ezemonye and Temiotan Emmanuel Ogbomida (2010)^[8] who have noted degeneration of hepatocytes, vacuolation and necrosis on the Gammalin 20 treated liver tissue of African cat fish *Clarius guricipinus*.

PLATE – 2



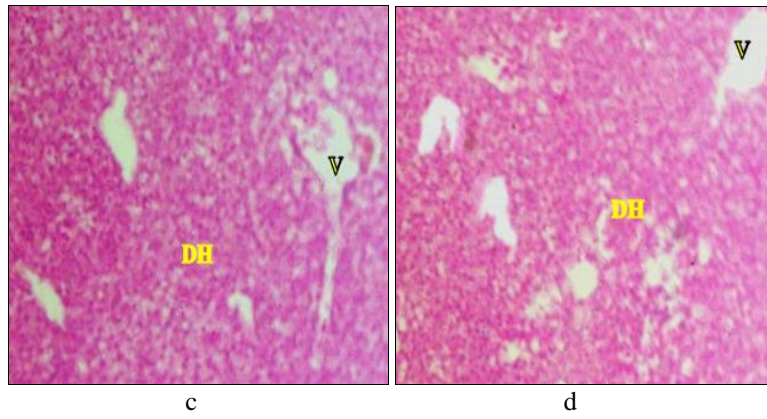


Plate - 2: Histopathological lesions in the liver of *Oreochromis mossambicus* exposed to 10% sublethal concentration of fipronil at different durations

a. Control

NH- Normal hepatocytes
BS - Blood sinus

b. 10 days treated

DCB- Disintegration of cell boundaries
DBS- Dilation of blood sinusoids

c. 20 days treated

V -Vacuolization
DH -Degeneration of hepatocytes

d. 30 days treated

V- Vacuolization
DH- Degeneration of hepatocyte

Fish exposed to the sublethal concentration of fipronil showed disintegration of renal epithelium, necrosis, and shrinkages of glomeruli in the kidney (Plate 3). Mohibul Hasan *et al.* (2022) ^[11] have also reported the histological changes in the kidney of Gourami fish due to the toxicity of thiamethoxam. The results of this present study are also supported by Manimekalai *et al.* (2022) ^[9] who observed necrosis and shrinkage of glomeruli in heptachlor pesticide treated tilapia fish.

PLATE - 3

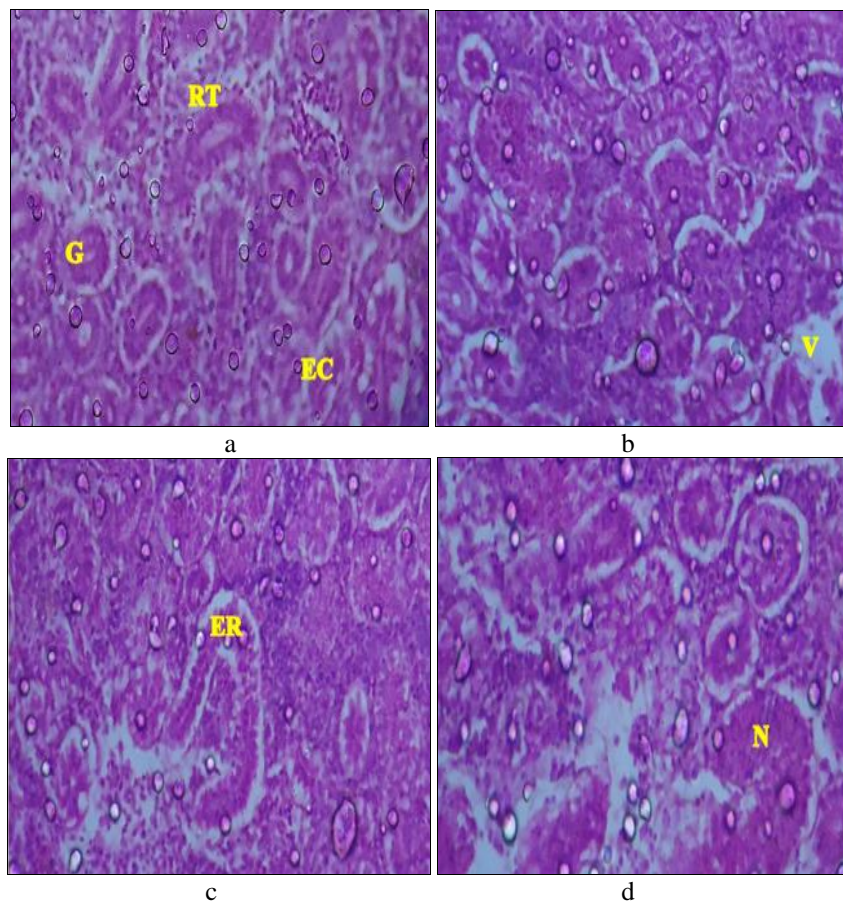


Plate- 3: Histopathological lesions in the kidney of *Oreochromis mossambicus* exposed to 10% sublethal concentration of fipronil at different durations

a. Control

G - Glomeruli
R - Renal tubules
EC - Epithelial Cells

b. 10 days treated

V - Vacuolization

c. 20 days treated

d. ER - Enlargement of renal tubule

e. 30 days treated

N - Necrosis

References

1. Agbohessi Prudencio, Houndji Alexis, Ouedraogo Alfred, Dandjinou Arlette, Houedjissi Gisèle, Imorou Toko Ibrahim *et al.* Haematoopoietic alterations induced by cotton insecticide Thalis 112 EC (Emamectin Benzoate 48 g/L, Acetamiprid 64 g/L) in African catfish *Clarias gariepinus*. *J. Toxicol. Risk Assess.*,2022;8:048:1-9.
2. Anupama, Amit Kumar Jha, Effects of cypermethrin on histopathology of gonads of a fresh water fish *Anabas testudineus* (Bloch.) Uttar Pradesh Journal of Zoology,2020;41(10):46-50.
3. Arumugam Stalin, Palani Suganthi, Subramanian Mathivani, Bilal Ahmad Paray, Mohammad K, Al-Sadoon. *Et al.* Impact of chlorpyrifos on behavior and histopathological indices in different tissues of freshwater fish *Channa punctatus* (Bloch). *Environmental Science and Pollution Research*,2019;26:17623-17631.
4. Bartosz Bojarski, Artur Osikowski, Sebastian Hofman, Leszek Szała, Joanna Szczygieł, Agnieszka Rombel-Bryzek. Effects of exposure to a glyphosate-based herbicide on haematological parameters, plasma biochemical indices and the microstructure of selected organs of the common carp (*Cyprinus carpio* Linnaeus, 1758). *Folia Biologica (Kraków)*,2022;70(4):213-229.
5. Finney DJ. *Probit Analysis*. Cambridge Univ. Press, London, 1971.
6. Humason SL. *Animal tissue technique*. III edition: W.H. Freeman and Co., San Fransisco, 1972.
7. Islam M, El-Garawani, Elsayed A Khallaf, Alaa A Alne-na-ei, Rehab G Elgendy, Hassan M *et al.* The effect of neonicotinoids exposure on *Oreochromis niloticus* histopathological alterations and genotoxicity. *Bulletin of Environmental Contamination and Toxicology*,2022;109:1001-1009.
8. Lawrence Ezemonye, Temiotan Emmanuel Ogbomida. Histopathological effects of Gammalin 20 on African catfish (*Clarias gariepinus*). *Applied and Environmental Soil Science Volume 2010*, Article ID 138019, 2010, 1- 8.
9. Manimekalai, Srinivasan D, Padmavathy A, Jawahar P, George R, Arisekar U. Acute and chronic toxicity effects of the heptachlor pesticide on tilapia (*Oreochromis mossambicus*): Impact to behavioural patterns and histopathological responses. *Journal of Coastal Research*,2022;38(5):999-1010.
10. Mohammad Amzad Hossain, LipiSutradhar,Tumpa Rani, Sarker Shuva Saha, Mohammed MahbubIqbal. Toxic effects of chlorpyrifos on the growth, hematology, and different organs histopathology of Nile tilapia, *Oreochromis niloticus*, *Saudi Journal of Biological Sciences*,2022;29(7):103316.
11. Mohibul Hasan Md, Md Helal Uddin, Md Jakiul Islam, Shema Biswas, Kizar Ahmed Sumon, Mohammad Dalower Hossain Prodhhan *et al.* Histopathological alterations in liver and kidney tissues of banded gourami (*Trichogaster fasciata*) exposed to Thiamethoxam, *Aquaculture Studies*,2022;23(1):1. AQUAST939.
12. Muhammad Fiaz Khan, Munawar Saleem Ahmad, Shehzad Ghayyur, Sajid Mahmood, Naveed Akhtar, Zaib Ullah *et al.* Comparative effects of selected agrochemicals on biochemical profile and histopathology of grass-carp (*Ctenopharyngodon idella*), *Pol. J. Environ. Stud.*,2022;31(2):1679-1691.
13. Noor S Jaffer, Adel M Rabee, Salah MM, Al-Chalabi. Biochemical and hematological parameters and histological alterations in fish *Cyprinus carpio* L. as biomarkers for water pollution with chlorpyrifos. *Human Ecological Risk Assessment: An International Journal*,2017;23(3):605-616.
14. Nor Azri-Shah Norhan, Mohd Ihwan Zakariah, Nurul Ulfah Karim, Hassan Mohd Daud, Anur Abdalah Nagi Melad, Nor Asma Husna Yusoff *et al.* Paraquat-induced histopathological changes on the gills, kidney and liver tissues of *Anabas testudineus* (Bloch 1792). *Journal of Sustainability Science and Management*,2022;17(8):169-1.
15. Rajesh K, Srivastava, Bushra Islam, Ashi Shukla, Arun Ratn. Impact of deltamethrin (2.8% EC) on serum biochemistry and histopathology of fish, *Channa punctatus* (Bloch 1793). *International Journal of Development Research*,2022;12(08):58223-58226.
16. Sprague JB. The ABC's of pollutant bioassays using fish. In: *Biological methods for the assessment of water quality*. ASTM STP,1973:528:6-30.
17. Tamil selvil R, Ilavazhahan M. Histopathological changes in gill tissue of the fish *Catla catla* exposed to sublethal concentration of pesticide methyl parathion and a heavy metal ferrous sulphate. *Biomedical and Pharmacology Journal*,2012;5(2):305-312.
18. Verma P, Kurikose S, Sawarkar DB. Histopathological effect of endosulfan on the kidney of *Clarias gariepinus* (Burchell, 1822) (Siluriformes: Clariidae) *Biological Forum – An International Journal*,2022;14(1):1439-1443.