



## Effect of ivermectin and moxidectin on the psoroptic mite infection confirmed by skin scrapings and a range of blood parameters of cattle in Al-Diwaniyah Province, Iraq

Sura Saad Hamada Alkhuzaie<sup>1</sup>, Asseel Yassin<sup>2</sup>

<sup>1</sup> Department of Veterinary Microbiology, College of Veterinary Medicine, University of Al-Qadisiyah, Al-Diwaniyah, Iraq

<sup>2</sup> Department of Anatomy and Histology, College of Veterinary Medicine, University of Al-Qadisiyah, Al-Diwaniyah, Iraq

### Abstract

The current study was conducted to study the effects of ivermectin and moxidectin on the Psoroptic mite infection in calves from Al-Diwaniyah Province, Iraq. The experiment included the use of 15 animals (6-10 months old and 100-120 kg of body weight), randomly divided into three groups (five animals per a group); An ivermectin (IM) group, in which IM was given subcutaneously (S/C) at 5ml/calf, a moxidectin (MD) group, in which MD was administered S/C at 5ml/calf, and a control (CL) group, in which no treatment was used. Skin scrapings and blood parameters, including complete blood count (CBC) and erythrocyte sedimentation rate (ESR), were used, for which blood samples were collected from all calves at before the treatments and 8, 16, and 24 days after treatments. The results showed that skin lesions disappeared after treatment for both acaricides, which was confirmed by the presence of no mites in the skin scrapings collected for each time point after treatment. Hemoglobin (Hb) was elevated significantly ( $p < 0.05$ ) after treatment in both treatment groups. Erythrocytes also revealed significant ( $p < 0.05$ ) increases after treatment in both treatment groups. For the leukocytes, the findings revealed significant ( $p < 0.05$ ) correction in their counts after treatment in both treatment groups. For eosinophils, MD showed a significant ( $p < 0.05$ ) effect in normalizing the levels of these blood cells but only after 24 days of treatment. In the case of monocytes, MD showed a significant ( $p < 0.05$ ) effect in decreasing the percentage of these cells after 8 and 16 days of treatment. No significant ( $p > 0.05$ ) effects were seen in the cases of lymphocytes, neutrophil segmented nucleus, granulocytes, and ESR. The study provides important information regarding the treatment effects of ivermectin and moxidectin not only against mites but also in the case of correcting blood parameters of calves, especially when moxidectin was used.

**Keywords:** ivermectin, mange, mites, moxidectin, psoroptes

### Introduction

In domesticated and wild animals, the worldwide Psoroptes mites (Acari: Psoroptidae) are key causative agent of mange, leading in substantial economic consequences and animal health issues. These mites can be found on any part of the skin but mainly in the inner side of the ears<sup>[1, 2]</sup>. To get lipid emulsion from the lymph, skin cells, and skin exudates, mite species; Psoroptes spp. abrade the epidermis. Inflammation, lymphoedema, and skin crusting are all possible complications of having active feeding mites on the skin. Hypersensitivity to mite coproantigens has been reported in humans. There is a risk of mortality from dehydration, pneumonia, or bacterial septicaemia in serious situations<sup>[3, 4]</sup>.

Psoroptes mites have an oval, somewhat dorso-ventrally flattened body shape. The genus Psoroptes is identified and classified at the species range by its morphological features. Specific pretarsal disk (a sucker-like ambulacral) on a long, 'segmented' ambulacral stalk differentiate the genus from other genera (5). Adult males' outer opisthosomal setae have long been utilized to differentiate the genus' five recognized species. Outer opisthosomal set length varies widely between and within communities of mites, although these changes are not linked to host species or regional backgrounds. As a result, the taxonomic viability of these taxa is still being debated<sup>[5, 6]</sup>. Industrialized nations like the United States and United Kingdom have generally eliminated the illness generated by Psoroptes mites (mainly subclinical infestations), but re-emergence in select places has been documented. The proliferation of mange mites has been aided in underdeveloped nations by inadequate hygienic and poor animal husbandry techniques<sup>[7, 8]</sup>. Topical amitraz and synthetic pyrethroids, as well as macrocyclic lactone (ML) parenteral injections, are the only approved therapies in Europe. It is not suggested that ML preparations be used topically owing to conflicting reports concerning their efficacy in eliminating *P. ovis*. Due to a lack of complete ovicidal activity, acaricides should be used twice with a 7–10-day interval. Because of their long-lasting effects, ML formulations only require a single application. Prior to treatment, the hair must be shaved and any crusts scraped off. Treatment should be administered to all animals that come into touch with infected animals, not only those who are clinically infected<sup>[9]</sup>.

## Materials and methods

### Experiment and tests

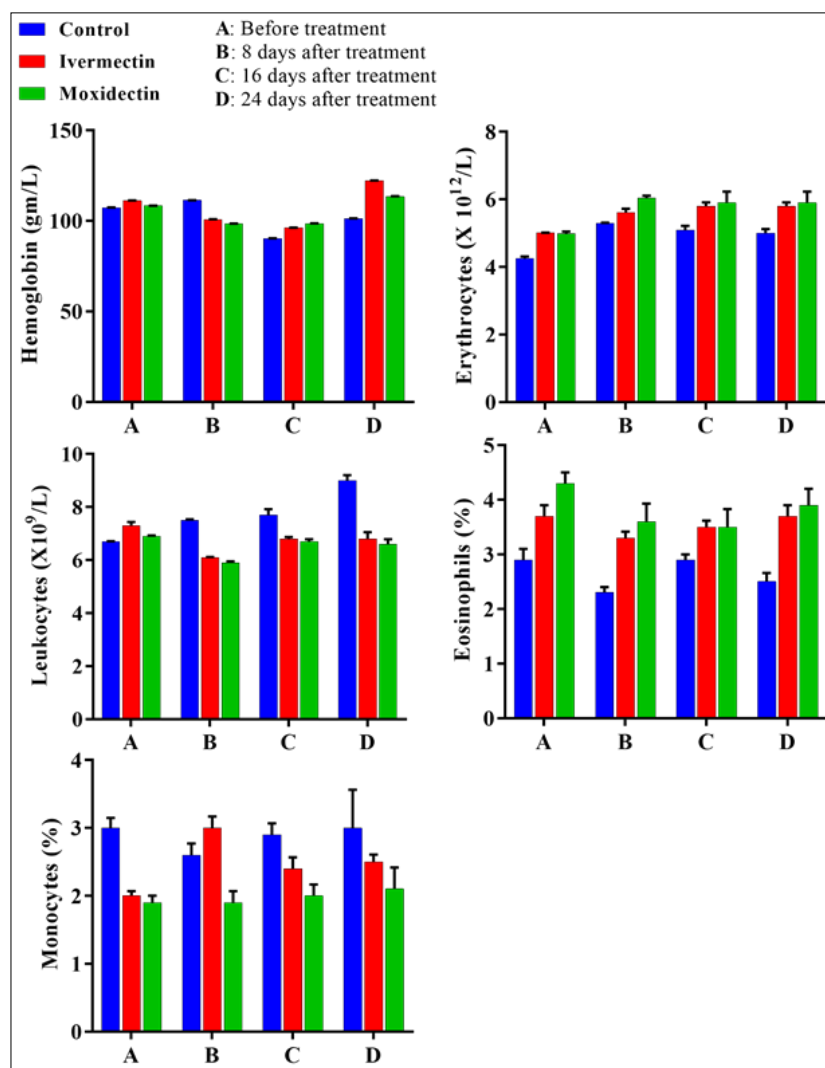
The study was conducted in the period of January 15 to April 25, 2021. The experiment included the use of 15 calves (6-10 months old and 100-120 kg of body weight), randomly divided into three groups (five animals per a group); The IM group, in which IM was given S/C at 5ml/calf, the MD group, in which MD was administered S/C at 5ml/calf, and the CL group, in which no treatment was used. Skin scrapings (9 cm<sup>2</sup>/sample) were collected from the lesion edges. The samples were 10°C-stored and analyzed within six hours after the sampling via the use of a stereoscopic microscope (100× of magnification). The mites were described according to previous methods by Van Mol *et al* [9]. The samples were collected in special containers from all calves at before the treatments and 8, 16, and 24 days after treatments and ice-box-transported to the Laboratory of Parasitology. CBC and ESR were performed.

### Statistical analysis

GraphPad Prism v7 (GraphPad Inc., USA) was employed to analyze the data via the use of a Two-Way ANOVA test. The level of significance at 5% was utilized for each test. Mean plus/minus standard error of mean (Mean±SEM) were recruited to analyze and display the processed data.

### Results

The results showed that skin lesions disappeared after treatment for both acaricides, which was confirmed by the presence of no mites in the skin scrapings collected for each time point after treatment. Hemoglobin (Hb) was elevated significantly ( $p<0.05$ ) after treatment in both treatment groups (Figure 1). Erythrocytes also revealed significant ( $p<0.05$ ) increases after treatment in both treatment groups (Figure 1). For the leukocytes, the findings revealed significant ( $p<0.05$ ) correction in their counts after treatment in both treatment groups (Figure 1). For eosinophils, MD showed a significant ( $p<0.05$ ) effect in normalizing the levels of these blood cells but only after 24 days of treatment (Figure 1). In the case of monocytes, MD showed a significant ( $p<0.05$ ) effect in decreasing the percentage of these cells after 8 and 16 days of treatment (Figure 1). No significant ( $p>0.05$ ) were seen in the cases of lymphocytes, neutrophil segmented nucleus, granulocytes, and ESR (Data not shown).



**Fig 1:** Effects of Ivermectin and Moxidectin on Psoroptic mites in calves

## Discussion

Mange describes a skin infection in animals generated by the parasite, mites, which characterized by itching, alopecia, crusty lesions and skin redness. The intense itchiness forces scratching body against any objects, resulting in skin damage, exposing skin to secondary pathogenic viral and bacterial illnesses. The identification of mange infection is established by clinical indications; however, they might be mimicked with certain other infections, including ringworm, ticks, and flea hypersensitivity <sup>[10]</sup>. Accordingly, laboratory detection by microscopic methods of ova, nymphs, and adult mites from skin scrapings is necessary for the validation of a diagnosis. The conventional microscopic diagnosis of mites with questionable sensitivity is solely performed globally, since there is no commercially accessible serological and molecular screening test with sufficient accuracy <sup>[11]</sup>. Our results agree with those mentioned above, in which the diagnosis of Psoroptic mites was confirmed by using a microscopic technique.

The treatment using ivermectin was successful in eliminating the skin lesions, which was confirmed microscopically in the tested skin scrapings. Hamel *et al* <sup>[12]</sup> used subcutaneously single dose of long-acting IM (at 1mL/50 kg bodyweight) injection against induced mite infestation of *Sarcoptes scabiei* var. *bovis* or *Psoroptes ovis* in cattle with collecting skin scrapings each week after treatment for eight weeks. Hamel *et al* <sup>[12]</sup> found that the animals treated with IM showed significant reduction in the numbers of mites present in the skin scrapings, and full clearance of animals from mites of both types was assured after 13 or 28 days of treatment. For the MD, the results of the present work revealed that skin was clear of mites after treatment with this acaricide. The findings, here, agree with those by Giadinis *et al* <sup>[13]</sup>, who used MD at 0.2 mg/kg S/C every two weeks in infested goats with mites and found a good response after the first dose of treatment but with complete skin healing after six weeks of treatment.

The correction in the levels of blood parameters recorded in the current study can be attributed to the use of treatment, which eliminated mites from the skin of infested calves. Mites are well known to cause draining of body blood and lymph contents via their pathological processes and feeding, which results in disturbances in the levels of these parameters, which were corrected after treatment <sup>[14-16]</sup>.

## Conclusion

The study provides important information regarding the treatment effects of ivermectin and moxidectin not only against mites but also in the case of correcting blood parameters of calves, especially when moxidectin was used.

## References

1. Losson BJ. Sheep psoroptic mange: an update. *Vet Parasitol* [Internet],2012;189(1):39-43. Available from: <https://pubmed.ncbi.nlm.nih.gov/22525584/>
2. Jones A, Caldow G, Cameron N, McGregor M. Psoroptic mange in a Scottish beef herd. *Vet Rec* [Internet],2014;174(20):509-10. Available from: <https://pubmed.ncbi.nlm.nih.gov/24832888/>
3. Shang X, Wang D, Miao X, Wang X, Li J, Yang Z, *et al*. The oxidative status and inflammatory level of the peripheral blood of rabbits infested with *Psoroptes cuniculi*. *Parasit Vectors* [Internet],2014;7(1):124-9. Available from: [/pmc/articles/PMC3972963/](https://pubmed.ncbi.nlm.nih.gov/253972963/)
4. Hallal-Calleros C, Morales-Montor J, Vázquez-Montiel JA, Hoffman KL, Nieto-Rodríguez A, Flores-Pérez FI. Hormonal and behavioral changes induced by acute and chronic experimental infestation with *Psoroptes cuniculi* in the domestic rabbit *Oryctolagus cuniculus*. *Parasit Vectors* [Internet],2013;6(1):361-70. Available from: [/pmc/articles/PMC3878243/](https://pubmed.ncbi.nlm.nih.gov/23878243/)
5. Amer S, El Wahab TA, El Naby Metwaly A, Feng Y, Xiao L. Morphologic and Genotypic Characterization of *Psoroptes* Mites from Water Buffaloes in Egypt. *PLoS One* [Internet],2015;10(10):e0141554-64. Available from: [/pmc/articles/PMC4627845/](https://pubmed.ncbi.nlm.nih.gov/2627845/)
6. Pegler KR, Evans L, Stevens JR, Wall R. Morphological and molecular comparison of host-derived populations of parasitic *Psoroptes* mites. *Med Vet Entomol* [Internet],2005;19(4):392-403. Available from: <https://pubmed.ncbi.nlm.nih.gov/16336304/>
7. Mitchell ES, Jones JR, Foster AP, Millar M, Milnes A, Williams J. Clinical features of psoroptic mange in cattle in England and Wales. *Vet Rec* [Internet],2012;170(14):364. Available from: <https://pubmed.ncbi.nlm.nih.gov/22427386/>
8. Bisdorff B, Wall R. Control and management of sheep mange and pediculosis in Great Britain. *Vet Parasitol* [Internet],2008;155(1-2):120-6. Available from: <https://pubmed.ncbi.nlm.nih.gov/18495347/>
9. Van Mol W, De Wilde N, Casaert S, Chen Z, Vanhecke M, Duchateau L *et al*. Resistance against macrocyclic lactones in *Psoroptes ovis* in cattle. *Parasit Vectors* [Internet],2020;13(1):135. Available from: [/pmc/articles/PMC7071684/](https://pubmed.ncbi.nlm.nih.gov/327071684/)
10. Asmare K, Abebe R, Sheferaw D, Krontveit RI, Barbara W. Mange mite infestation in small ruminants in Ethiopia: Systematic review and meta-analysis. *Vet Parasitol* [Internet],2016;218(3):73-81. Available from: <https://pubmed.ncbi.nlm.nih.gov/26872931/>
11. Ali A, Hameed K, Mohsin M, Khan W, Rafiq N, Iqbal MA *et al*. Prevalence and risk factors assessment of mange mites in livestock of Malakand Division, Pakistan. *Saudi J Biol Sci* [Internet],2021;28(11):6480-7. Available from: [/pmc/articles/PMC8568703/](https://pubmed.ncbi.nlm.nih.gov/348568703/)

12. Hamel D, Joachim A, Löwenstein M, Pfister K, Silaghi C, Visser M *et al.* Treatment and control of bovine sarcoptic and psoroptic mange infestation with ivermectin long-acting injectable (IVOMEC(®) GOLD). *Parasitol Res* [Internet],2015;114(2):535-42. Available from: <https://pubmed.ncbi.nlm.nih.gov/25399813/>
13. Giadinis ND, Farmaki R, Papaioannou N, Papadopoulos E, Karatzias H, Koutinas AF, *et al.* Moxidectin Efficacy in a Goat Herd with Chronic and Generalized Sarcoptic Mange. *Vet Med Int* [Internet]. 2011 [cited 2022 Mar 28],2011;5:476348-51. Available from: </pmc/articles/PMC3135081/>
14. Fesseha H, Etana E, Mathewos M. Mange Mites of Goats in Malle District of South Omo Zone, Southern Ethiopia. *Vet Med Res Reports* [Internet],2021;12(6):159-68. Available from: </pmc/articles/PMC8200143/>
15. Salem HM, Yehia N, Al-Otaibi S, El-Shehawi AM, Elrys AAME, El-Saadony MT, *et al.* The prevalence and intensity of external parasites in domestic pigeons (*Columba livia domestica*) in Egypt with special reference to the role of deltamethrin as insecticidal agent. *Saudi J Biol Sci* [Internet],2022::29(3):1825-31. Available from: </pmc/articles/PMC8913344/>
16. Geddes E, Mohr S, Mitchell ES, Robertson S, Brzozowska AM, Burgess STG *et al.* Exploiting Scanning Surveillance Data to Inform Future Strategies for the Control of Endemic Diseases: The Example of Sheep Scab. *Front Vet Sci* [Internet],2021;8(7):647722. Available from: </pmc/articles/PMC8322841/>