

## Histopathological effects on the male reproductive system of the oriental latrine fly, *Chrysomya megacephala* (Fabricius) (Diptera: Calliphoridae) induced by Deltamethrin

Ritika Gupta, Mohammad Amir

Department of Zoology, Aligarh Muslim University, Aligarh, Uttar Pradesh, India

### Abstract

*Chrysomya megacephala* (Fabricius) (Diptera: Calliphoridae), a species belonging to the family Calliphoridae, commonly known as Oriental latrine fly is a synanthropic fly. Its importance in medical and forensic entomology is very eminent. In spite of having advantages in forensic entomology, its effect on humans and animals is very serious as it causes myiasis, and various other pathogenic diseases. In our study, the effect of deltamethrin at sub lethal doses (0.005%, 0.001%, 0.0005%) and at two different post treatment periods (24 hours and 48 hours) was studied on the testis of *Chrysomya megacephala*. Deltamethrin was found to be effectual in inducing abnormalities on the male reproductive system. Histological investigation of testis illustrated disruption and detachment of the epithelium from the testicular tissue, necrosis, pycnosis and reduction in number of spermatocytes, spermatogonia and spermatozoa. Vacuolization in all the zones and disappearance of sperm bundles is also seen. All these effects were directly correlated with that of the dose of insecticide as well as the post treatment period and with the increase in concentration and the timing, the effects became more prominent.

**Keywords:** histopathology, testis, deltamethrin, *Chrysomya megacephala*

### Introduction

The blowfly, *Chrysomya megacephala* (Fabricius), a member of the family Calliphoridae, is a necrophagus dipteran, one of the dominant flies of forensics. Flies are the first insects to arrive at putrefied remains and thus used as a death investigator in forensic entomology. It is geographically distributed over a wide area of the Oriental, Australasian and Oceania regions of the world, and extends as far as Africa, South America and Central America.

Although having an importance in forensic entomology, it is involved in causing accidental myiasis<sup>[1]</sup> and mechanically transmitting bacteria and viruses under unsanitary conditions to human food that causes diseases in humans and animals<sup>[2-8]</sup>. Deltamethrin is a synthetic pyrethroid and is considerably less harmful to the environment and most non-target organisms than any other insecticides<sup>[9]</sup>. Deltamethrin has a rapidly disabling effect on insects. Deltamethrin's mode of action is its irreversible damage to the nervous system occurring when poisoning lasts more than a few hours. Deltamethrin has very broad-spectrum control and is considered the most powerful of the synthetic pyrethroids.

Extensive work on the histopathology of testis of various insect orders has been performed by renowned investigators and very illustrious results has been obtained showing the destruction in the various stages of development in *Hippelatus pusio* treated with apholate, tepa, metepa<sup>[10]</sup>, in *Musca domestica* treated with chemosterilants<sup>[11]</sup>, in *Locusta migratoria* treated with tepa and apholate<sup>[12, 13]</sup>, in *Poeciloceris pictus* treated with endosulfan<sup>[14]</sup>, in *Bactrocera zonata* treated with gamma radiation<sup>[15]</sup>, in *Heteracris littoralis* treated with azadirachtin<sup>[16]</sup>, in *Damalinea limbata* treated with neem azal<sup>[17]</sup>, in *Blatella germanica* treated with

pyriproxyfen<sup>[18]</sup>, in *Nilaparvata lugens* treated with azadirachtin<sup>[19]</sup>, in *Chrotogonus trachypterus* treated with cypermethrin and Monocrotophos<sup>[20, 21]</sup>, in *Schistocerca gregaria* treated with insect growth regulators<sup>[22]</sup>, in *Rhynchophorus ferrugineus* treated with neem and flufenoxuron<sup>[23]</sup>, in *Heteracris littoralis* treated with Botanical insecticide<sup>[24]</sup>, and in *Sarcophaga ruficornis* treated with dieldrin, fenthion, carbaryl and Deltamethrin<sup>[25]</sup>.

From the above mentioned works, it is clear that the histopathology on the male reproductive system of dipterans is meagre, so an attempt has been made to examine the histology of the testis of the *Chrysomya megacephala* treated with pyrethroid insecticide Deltamethrin.

### Material and Methods

#### Breeding and Maintenance of *Chrysomya megacephala*

*Chrysomya megacephala* flies were collected from the Aligarh Muslim university campus and brought to the laboratory for research work. The flies were kept in cages made of wire mesh and ply board. Breeding of the flies was done as per the earlier work of author<sup>[26]</sup>.

#### Sampling of Experimental Insects

On the 5<sup>th</sup> day of the adult emergence, the male flies were treated with the insecticide deltamethrin in the concentration 0.005%, 0.001%, 0.0005% by ingestion method to obtain histopathological results on testis of the fly.

#### Histological Preparation of Testis for Light Microscopy

Control as well treated flies were dissected in insect Ringer's solution under dissecting microscope after 24 hrs of treatment. Testis were excised and fixed immediately in Bouin's solution

for 18 hrs and then dehydrated in ascending grades of alcohol 30%, 50%, 70%, 80%, 90%, for 15 mins each while in 96% and 100% for half an hour each followed by 100% alcohol and xylene solution (1:1) for 10 mins. Incubation was done at 60°C in xylene and paraffin wax (1:1) for 15 mins and then in pure wax for 1 hour. Testis was then embedded in paraffin wax whose 5µm microtome sections were cut. Ribbons were placed on glass slide which was lubricated by glycerine and egg albumin solution. The slides were then stretched on warming table to remove creases. Slides were then processed in 2 changes of xylene and then in descending grades of alcohol series 100%, 96%, 90%, 80%, 70%, 50%, 30% for 5 mins each and then in distilled water for 5 mins each. Slides were stained in Delafields haematoxylin for 10 seconds and then washed in tap water and counterstained with alcoholic eosin for 20 minutes followed by upgrade dehydration of alcohol for 5 mins each and then 2 changes of xylene for 10 mins each. Slides were then mounted in DPX to observe under the compound light microscope. Photographs were taken using Nikon Eclipse compound microscope by taking appropriate magnification. Histological preparation for the control flies was also done to compare the effects.

## Results and Discussion

### Normal Histology of Testis of *C. megacephala* (Figs. 1&2)

The male reproductive system is located in the posterior portion of the abdomen and typically consists of paired testes, a pair of vasa deferentia, a pair of accessory glands and the ejaculatory duct with ejaculatory sac which opens to the exterior by aedeagus. Accessory glands are usually associated with a duct<sup>[27]</sup>.

Testes are bilateral and paired structure, consists of a single sperm follicle. The wall of the testis consists of two layers, a tunica interna and tunica externa. The tunica interna (Ti) is a thick syncytial layer and contains large oval nuclei scattered under no definite plan. The tunica externa (Te) is comparatively thin containing small oval nuclei and large amount of pigment granules which impart an orange brown colour to the testis. The lumen of the testis contains the germ cells in various stages of development. Histologically, the testis can be divided into a number of zones on the basis of the developmental stages of germ cells.

#### 1. Zone of Spermatogonia and Spermatocytes (ZSpgSpc):

The apical portion of the testis, the germarium presents a densely packed mass of germ cells. The primary germ cells are the spermatogonia (Spg). As the spermatogenesis proceeds, the spermatogonium subdivides and the daughter spermatogonia are encysted to form the sperm cysts which are known as spermatocytes (Cst).

#### 2. Zone of Maturation and Reduction (ZMatRed):

The small zone of spermatocytes is followed by a comparatively larger zone of maturation and reduction. In this zone the spermatocytes divide to form the binucleate and tetranucleate stages.

#### 3. Zone of Transformation (ZTrans):

It is the largest portion of the testis. It is mostly occupied by spermatids (Spd) and spermatozoa (Spz). The spermatocytes develop into spermatids. The latter are transformed into bundles of mature spermatozoa called spermatodesms. The free spermatozoa were not observed in the lumen of the testis.

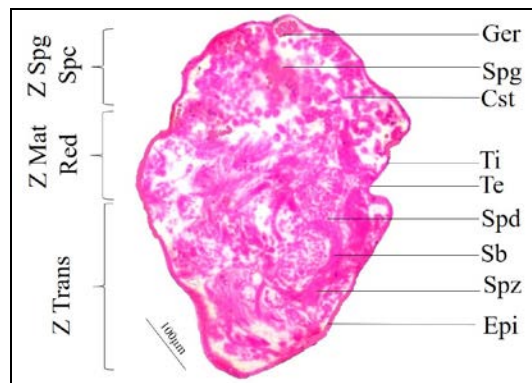


Fig 1: LS of control Testis of *Chrysomya megacephala* (10X)

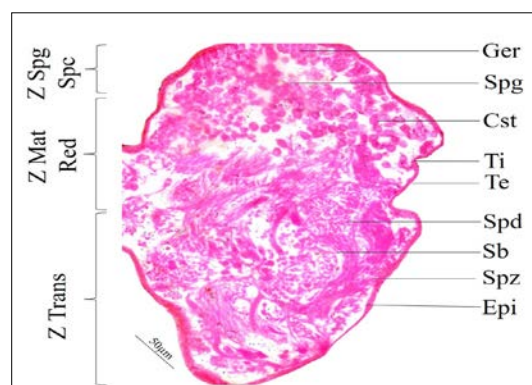


Fig 2: LS of control Testis of *Chrysomya megacephala* (40X)

### Histopathological effects on Testis (Figs. 3-14)

Histological changes in the testis treated with sub lethal doses 0.005%, 0.001%, 0.0005% at two different time periods (24 hours & 48 hours) were examined.

Present study deals with basic histology of the testis which has been distorted after the application of 3 sublethal insecticide doses, at lower doses the zones are somewhat identifiable but as the doses increased the damage continued to increase enormously.

Marked reduction in the number of spermatogonia, spermatocytes, and spermatozoa was seen, at lower concentration 0.0005% and all the cells were scattered near the middle of the testis after the 24 hours of treatment. Increasing the timing of dose treatment i.e. after 48 hours the cells got clumped more towards the centre. In comparison to this, the cells were very few in number at higher dose 0.001% which further decreased after prolonging the time period and at 0.005% concentration the cells were severely reduced which further showed prominence after 48 hours of treatment. Similar observations were seen by Sharaby *et al.*<sup>[24]</sup> in the testis of *Heteracris littoralis* treated with alcoholic extracts of five medicinal plants, by El-Bokl *et al.*<sup>[23]</sup> in the testis of *Rhynchophorus ferrugineus* treated with some insecticidal agents and by Amir<sup>[25]</sup> who observed similar effects of with dieldrin, deltamethrin, fenthion and carbaryl on the testis of *Sarcophaga ruficornis*. Similar findings were also made by Linton *et al.*<sup>[28]</sup> on the testis of *Schistocerca gregaria* treated with azadirachtin, by Wilson and Hays<sup>[11]</sup> on the testis of *Musca domestica* treated with chemosterilants, by Younes<sup>[29]</sup> who showed the effect of gamma radiation on the testis of

*Galleria mellonella* and by Mohamed *et al.*<sup>[30]</sup> who applied neem azal on the testis of *M. domestica*.

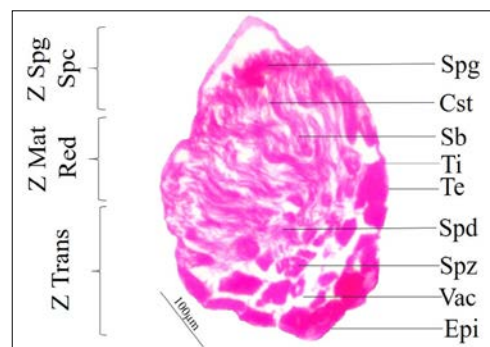
Necrosis in all the spermatogenic zones is quite distinctly evident in the present findings at different concentrations. These abnormalities were also observed in that of *P. pictus* treated with apholate and tepa by Saxena and Aditya<sup>[31,32]</sup>, in *S. ruficornis* treated with dieldrin, deltamethrin, fenthion and carbaryl by Amir<sup>[25]</sup>, in *P. Pictus* after treatment with apholate by Sheikher & Mittal<sup>[33]</sup>, in *E. insulana* treated with pyriproxyfen by Hussein *et al.*<sup>[34]</sup>, in *H. littoralis* when treated with azadirachtin by Ghazawi *et al.*<sup>[16]</sup>, in *L. migratoria* after treatment with tepa and apholate by Nath *et al.*<sup>[12, 13]</sup>, in *Schistocerca gregaria* treated with insecticidal agent by Mohammed and El-Gammal<sup>[35]</sup>.

Pycnosis in the spermatocytes and spermatogonia was clearly visible. At higher concentration (0.005%) almost all the cells showed pycnosis after 24 hours, increasing the dose treatment timing (48 hours) displayed more prominency. At 0.001%, the pycnosis was observed in lesser number of cells which further decreased at 0.0005%. The observed pycnosis in testis is in accordance with the results shown by Janak<sup>[14]</sup> on *P. pictus* treated with endosulfan, by Saxena and Aditya<sup>[29, 30]</sup> on *P. pictus* treated with chemosterilant, by Amir<sup>[25]</sup> on *S. ruficornis* treated with dieldrin, deltamethrin, fenthion, and carbaryl, by Nath *et al.*<sup>[12, 13]</sup> who treated *L. migratoria* with tepa and apholate, and also on *C. trachypterus* treated with monocrotophos and cypermethrin by Shakeet and Bakshi<sup>[20,21]</sup>. Disruption of sperm bundles with the appearance of vacuoles at 0.005% concentration was prominent after 24 hours, which became more detectable after 48 hours. At 0.001% and 0.0005% concentration, little disruption with smaller sized vacuoles was observed. Ghazawi<sup>[16]</sup> also reported the similar effects on *H. littoralis* treated with azadirachtin and Shehata<sup>[15]</sup> described the similar effects of gamma radiation on *Bactrocera zonata*.

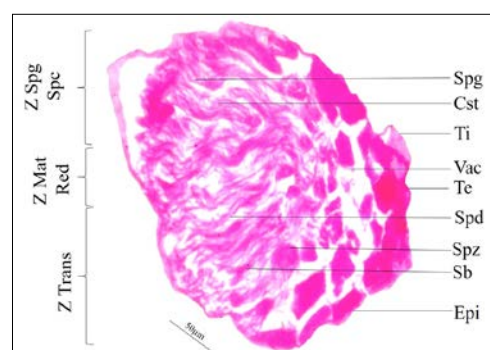
Vacuolization in the germarium region was prominent in all the concentration. This result agrees with that on *S. ruficornis* after treatment with deltamethrin, dieldrin, fenthion and carbaryl by Amir<sup>[25]</sup>, on *P. pictus* treated with chemosterilants by Saxena and Aditya<sup>[31, 32]</sup>, on *L. migratoria* treated with tepa and apholate by Nath *et al.*<sup>[12, 13]</sup>.

Deformities, thinning, detachment from the testicular tissue and number of folding were observed in the testicular epithelium. At 0.0005% concentration of insecticide, epithelium at the apical region showed detachment with only few folds after 24 hours of application and number of folds increased after 48 hours, while at 0.001% concentration thinning in the epithelium started, disruption increased, epithelium moved farther apart from the testicular tissue, and at 0.005% distortion was more prominent with further increase in the folding of epithelium and thinning further increased after 48 hours. Histological destruction detected in the present study are similar to that demonstrated in different insects. Ghazawi<sup>[16]</sup> observed the similar effects on the testis of *H. littoralis* treated with azadirachtin, Shehata<sup>[15]</sup> viewed misshaped epithelial layer in *B. zonata* treated with gamma radiation. Shakeet and Bakshi<sup>[20, 21]</sup> also detected the protusion in the testicular wall along the periphery in *C. trachypterus* treated with cypermethrin and monocrotophos. Amir<sup>[25]</sup> studied the similar disruptions in *S. ruficornis* treated

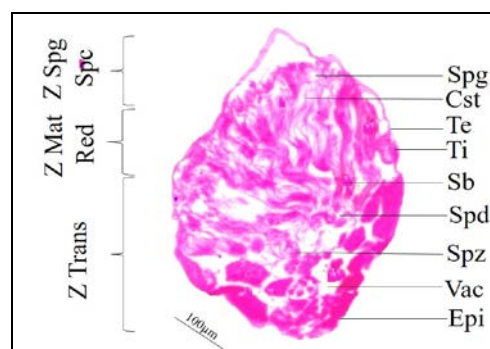
with deltamethrin, dieldrin, fenthion and carbaryl and also by Nath *et al.*<sup>[12, 13]</sup> in *L. migratoria* treated with tepa and apholate.



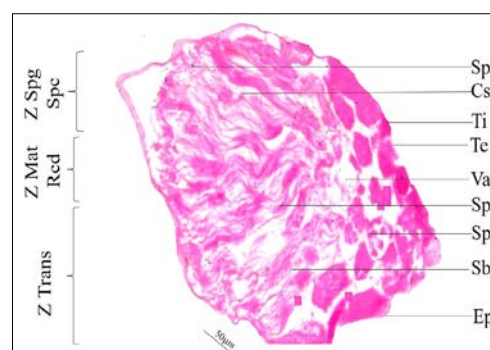
**Fig 3:** LS of Testis of *C. megacephala* treated with 0.005% Deltamethrin after 24 hours (10X)



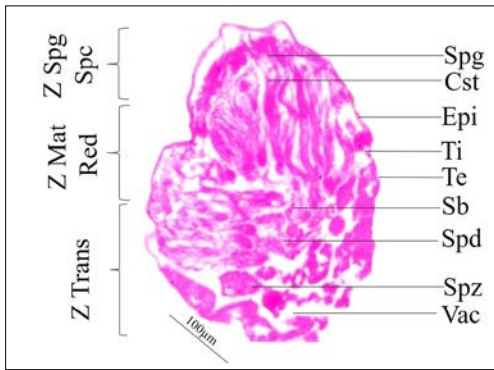
**Fig 4:** LS of Testis of *C. megacephala* treated with 0.005% Deltamethrin after 24 hours (40X)



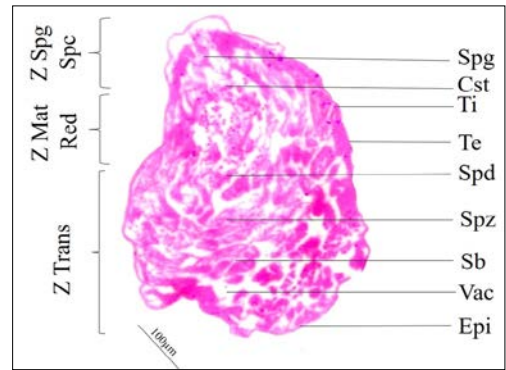
**Fig 5:** LS of Testis of *C. megacephala* treated with 0.005% Deltamethrin after 48 hours (10X)



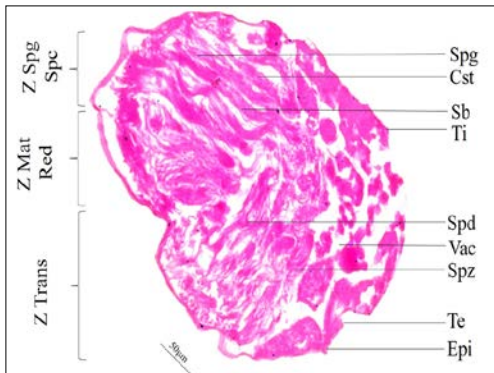
**Fig 6:** LS of Testis of *C. megacephala* treated with 0.005% Deltamethrin after 48 hours (40X)



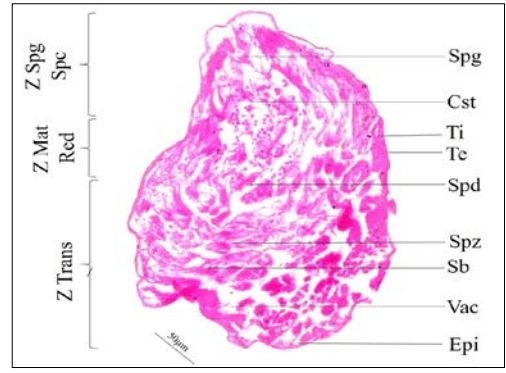
**Fig 7:** LS of Testis of *C. megacephala* treated with 0.001% Deltamethrin after 24 hours (10X)



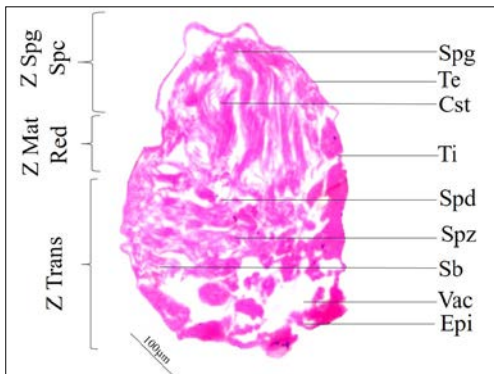
**Fig 11:** LS of Testis of *C. megacephala* treated with 0.005% Deltamethrin after 24 hours (10X)



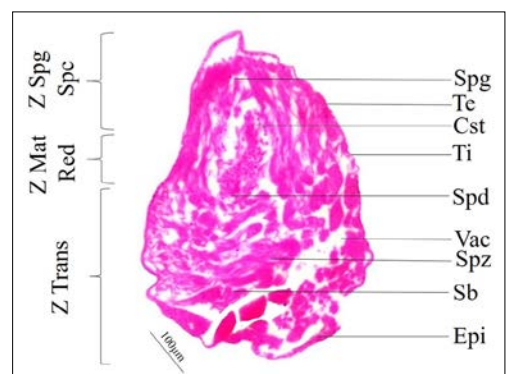
**Fig 8:** LS of Testis of *C. megacephala* treated with 0.001% Deltamethrin after 24 hours (10X)



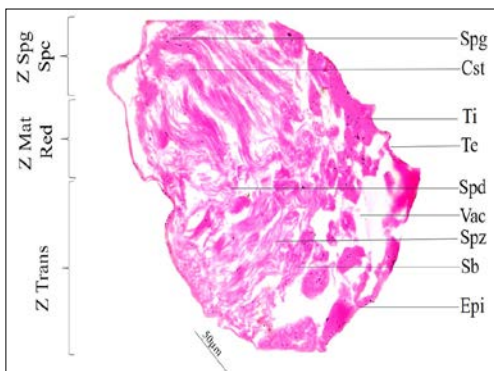
**Fig 12:** LS of Testis of *C. megacephala* treated with 0.005% Deltamethrin after 24 hours (40X)



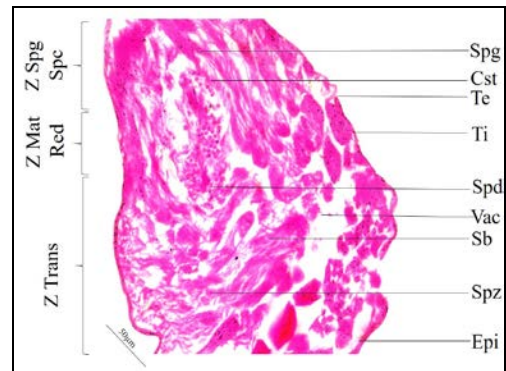
**Fig 9:** LS of Testis of *C. megacephala* treated with 0.001% Deltamethrin after 48 hours (10X)



**Fig 13:** LS of Testis of *C. megacephala* treated with 0.005% Deltamethrin after 48 hours (10X)



**Fig 10:** LS of Testis of *C. megacephala* treated with 0.001% Deltamethrin after 48 hours (40X)



**Fig 14:** LS of Testis of *C. megacephala* treated with 0.005% Deltamethrin after 48 hours (10X)

### Acknowledgement

First author wishes to express sincere thanks to the University Grants Commission for providing financial assistance in the form of research fellowship (Non-Net UGC Fellowship) during the course of the work.

### References

- Zumpt. Myiasis in man and animals in the Old World: a textbook for physicians, veterinarians and zoologists. Butterworth; London, UK, 1965, 267.
- Greenberg B. Flies and disease. Ecology, classification and biotic associations. Princeton, NJ: Princeton University Press, 1971, 1.
- Greenberg B. Flies and disease. Biology and disease transmission. Princeton, NJ: Princeton University Press, 1973, 2.
- Greenberg B. *Chrysomya megacephala* (F) (Diptera: Calliphoridae) collected in North America and notes on *Chrysomya* species present in the New World. Journal of Medical Entomology. 1988; 25:199-200.
- Baumgartner DL and Greenberg B. The genus *Chrysomya* (Diptera: Calliphoridae). Journal of Medical Entomology. 1984; 21:105-113.
- Monzon RB, Sanchez AR, Tadianan BM, Najos OA, Valencia EG, deRueda RR, *et al.* A comparison of the role of *Musca domestica* (Linnaeus) and *Chrysomya megacephala* (Fabricius) as mechanical vectors of helminthic parasites in a typical slum area of Metropolitan Manila. Southeast Asian Journal of Tropical Medicine Public Health. 1991; 22:222-228.
- Wells JD. *Chrysomya megacephala* (Diptera: Calliphoridae) has reached the continental United states: Review of its biology, pest status and spread around the world. Journal of Medical Entomology. 1991; 28:471-473.
- Maldonado MA, Centeno N. Quantifying the potential pathogens transmission of the blowflies (Diptera: Calliphoridae). Memorias do Instituto Oswaldo Cruz. 2003; 98:213-216.
- Adelsbach TL, Tjeerdema RS. Chemistry and fate of fenvalerate and esfenvalerate. Reviews of Environmental Contamination and Toxicology. 2003; 176:137-154.
- Schwartz PH. and Jr. Effect of apholate, metepa and tepa on reproductive tissues of *Hippelates pusio*. Journal of Invertebrate Pathology. 1965; 7:18-151.
- Wilson JA, Hays SB. Histological changes in the gonads and reproductive behaviour of house flies following treatment with chemosterilant p,p-bis (1-aziridinyl)-N-(3-methoxypropyl) phosphinothioic acid. Journal of Economic Entomology. 1969; 62:690-692.
- Nath V, Mittal PK, Sheikher C. Necrosis induced by tepa in the gonads of *Locusta migratoria* (L). Israel Journal of Entomology. 1975; 9:29-40.
- Nath V, Mittal PK, Sheikher C. Effect of apholate on the gonads of *Locusta migratoria*. Indian Journal of Entomology. 1978; 40(1):74-80.
- Janak A. Necrosis induced by an organochlorine pesticide (endosulfan) in the gonads of orthopteran insect, *Poeciloceris pictus* (F). Proceeding of Academy of Environment and Biology. 1992; 1(2):159-164.
- Shehata MF, Younes MWF and Mahmoud YA. Histopathological effects of gamma radiation on the peach fruit fly, *Bactrocera zonata* (Saund.) male gonads. Journal of Applied Sciences Research. 2008; 2(11):1053-1058.
- Ghazawi NA, El-Shranoubi ED, El-Shazly MM, Abdel Rahman KM. Effects of azadirachtin on mortality rate and reproductive system of the grasshopper *Heteracris littoralis* Ramb. (Orthoptera: Acrididae). Journal of Orthoptera Research. 2007; 16:57-65.
- Habluetzel A, Carnevali F, Lucantoni L, Grana L, Attili AR, Archilei F, *et al.* Impact of the botanical insecticide Neem Azal on survival and reproduction of the biting louse *Damalinia limbata* on angora goats. Veterinary Parasitology. 2007; 144:328-337.
- Fathpour H, Noori A, Zeinali B. Effects of juvenoid pyriproxyfen on reproductive organ, development and reproduction in German cockroach Dictyoptera: Blattellidae. Iranian Journal of Science and Technology. 2007; 31:89-98.
- Senthil NS, Young CM, Yul SH, Hoon PC, Kalaivani K Duk KJ. Effect of azadiractin on acetylcholinesterase (AChE) activity and histology of the brown planthopper *Nilaparvata lugens* (Stal.). Ecotoxicology and Environment Safety. 2008; 70:244-250.
- Shakeet P, Bakshi S. Histopathological effect of cypermethrin on gonads of *Chrotogonus trachypterus* Blanchard Orthoptera: Acrididae. Pakistan Entomology. 2009a; 31(1):17-24.
- Shakeet P, Bakshi S. Histopathology of gonads of *Chrotogonus trachypterus* (Blanchard) with sublethal dose of monocrotophos. Karnataka Journal of Agricultural Science. 2009b; 22:507-510.
- Reda FAB, Mona IM, Abd-Elazeem ME, Noura MM. Histopathological change in the testis of the desert locust *Schistocerca gregaria* (Forskell) induced by the IGR Consult and Lufox. Egyptian Academy Journal of Biological Sciences. 2010; 1:23-28.
- El-Bokl MM, Bakr RFA, El-Gammal HL, Mahmoud MZ. Biological and histopathological effects of some insecticidal agents against red palm weevil *Rhynchophorus ferrugineus*. Egyptian Academy Journal of Biological Sciences. 2010; 1:7-22.
- Sharaby A, Montasser SA, Shamseldean MM, Mahmoud YA, Ibrahim SA. Plant extracts as alternative botanical insecticide for control of the grasshopper *Heteracris littoralis* Ramb. (Orthoptera: Acrididae) with reference to histological changes on the reproductive system. Journal of Basic and Applied Scientific Research. 2011; 1(9):1031-1038.
- Amir M. Histopathological effect of some insecticides on the Male reproductive system of *Sarcophaga ruficornis* (Fabricius) (Diptera: Sarcophagidae). Journal of Entomology and Zoology Studies. 2016; 4(5):860-864.
- Gupta R, Amir M. Histopathological effects of deltamethrin on the ovaries of oriental latrine fly, *Chrysomya megacephala* (Fabricius) Diptera: Calliphoridae. Journal of Global biosciences. 2016; 5:4036-4042.

27. Bansal A, Murad H. Morphology of the female reproductive organs of the oriental latrine fly, *Chrysomya megacephala* (Fabricius). Japanese Journal of Sanitary Zoology. 1987; 38:233-238.
28. Linton YM, Nisbet AJ, Mordue AJ. The effect of azadirachtin on the testes of desert locust, *Schistocerca gregaria* Forskal. Journal of Insect Physiology. 1997; 43:1077-1084.
29. Younes MWF, Ryan MF, Emara TEA. Histopathological effects of gamma radiation on the testis and ovary of the greater wax moth *Galleria mellonella* (L) (Lepidoptera: Galleridae). Journal of the Association of Arab Universities for Basic and Applied Sciences. 1994; 1:209-238.
30. Mohamed HA, Bream AS, Ghneim KS. Developmental and reproductive responses of house fly *Musca domestica* (Diptera: Muscidae) to the neem seed extracts, Neem Azal. Journal of the Egyptian German Society of Zoology. 2000; 31:235-249.
31. Saxena SC, Aditya V. Histopathology and histochemistry of the insects treated with chemosterilants II. On the studies of DNA in active testis of *Poeciloceris pictus*. Cytologia. 1969; 34:405-407.
32. Saxena SC, Aditya V. Histopathology and histochemistry of the insects treated with chemosterilants III. Nucleic acid, phospholipids and phosphatases in the testis of chemosterilized *Poeciloceris pictus*. Israel Journal of Entomology. 1971; 6:195-210.
33. Sheikher C, Mittal PK. Cytochemical changes induced by apholate, tepa and hempa in the testes of *Locusta migratoria* (L). Indian Journal of Entomology. 1986; 48(3):289-291.
34. Hussein NM, Enan RA and Mohamed MI. Effects of the juvenoid pyriproxyfen on gonad development in male *Earias insulana* (Boisd.) (Lepidoptera: Noctuidae). Agricultural Research. 1993; 17:129-140.
35. Mohammed MT, EL-Gammal AM. Insect regulatory effect containing preparation on the Desert locust, *Schistocerca gregaria* (Orthoptera: Acrididae). Egyptian Journal of Agricultural Research. 2002; 80(1):189-202.